AFAST® Introduction and Its Target Organ Approach – Everyday Extension of Your Physical Exam

Emerald Coast Veterinary Conference, Sandestin, FL, USA
Gregory R. Lisciandro, DVM, Dipl. ABVP, Dipl. ACVECC
Hill Country Veterinary Specialists & FASTVet.com, Spicewood, Texas USA
Email LearnGlobalFAST@gmail.com
Cell 210.260.5576
Website FASTVet.com

Textbook Point-of-care Ultrasound Techniques for the Small Animal Practitioner, 2nd Edition, Wiley ©2021

Introduction

The clinical utility of AFAST®, its target-organ approach and its applied fluid scoring system may be used in virtually all subsets of patients including trauma, triage (non-trauma) and tracking (monitoring) cases in the emergent and critical care settings. The previously published T^3 designation encompasses these 3 subsets, Trauma, Triage (non-trauma), and Tracking (monitoring) and avoids the onslaught of confusing acronyms and terms in human medicine and now veterinary medicine.

However, AFAST® has become a universal acronym and now used "an extension of the physical examination" and thus the T^3 designation is unnecessary as more and more veterinarians understand its daily applications to nearly all patients. Most importantly, AFAST® has *exact* clarity to its standardized 5-acoustic windows or views so colleagues know exactly what ultrasound study is being performed (Lisciandro et al. 2009; Lisciandro 2011, 2014, 2016, 2020; Boysen and Lisciandro 2013; McMurray et al. 2016).

The AFAST® examination carries greater potential to positively guide clinical course and improve patient outcome by detecting conditions and complications otherwise missed or delayed based on traditional first line evaluation of physical examination, laboratory testing, and radiographic finding. AFAST® findings are made more clinically relevant for the clinician, client, and referring veterinarian by using its standardized ultrasound format, and by recording AFAST® findings on standardized goal-directed templates for medical records (see below).

The mindset for those using AFAST® is one of a *ruling in* and *ruling out* test (highly specific and highly sensitive) for the presence or absence of free fluid, and a *ruling in* test for soft tissue abnormalities of its target-organ (highly specific and variably [user-dependent] sensitive). In other words, AFAST® serves as a screening test for obvious abnormalities of its target-organs. In other words, if you see an abnormality it's likely real; however, if you don't see an abnormality, then it may have been missed, being user-dependent keeping in mind our training is not the same as a radiologist or cardiologist. Thus, AFAST® is not intended to replace a complete detailed abdominal ultrasound.

AFAST® can answer many clinical questions within its 5-view framework. AFAST® has an applied abdominal fluid scoring system that helps semi-quantify effusions and help with decision-making regarding medical versus surgical cases including the need for blood transfusion(s), exploratory surgery, and other interventions in both bleeding and non-hemorrhaging patients. Moreover, the AFAST® Cysto-Colic View urinary bladder volume estimation formula provides a means to estimate urine volume and thus over time a means to non-invasively estimate urine output (Lisciandro and Fosgate 2017). Pneumoperitoneum, gastrointestinal peristalsis, renal perfusion, volume status and intrathoracic abnormalities are added AFAST® clinical information gained without any additional views.

The standardization and clarity of Global FAST®, the term used for combining AFAST®, TFAST® and Vet BLUE®, is the author's recommended approach for using FAST and point-of-care ultrasound (POCUS) because it avoids "selective imaging" and "satisfaction of search error." "Selective imaging" leads to "confirmation bias error", searching for evidence to fulfill the clinician's preconceived bias for the diagnosis. For example, you wouldn't only palpate the abdomen in a vomiting patient, thus you shouldn't selectively image.

"Satisfaction of search error" is common in radiology and occurs when the evaluator stops at the first abnormality carrying the potential to miss other important findings. Advantageously, the Global FAST® Approach provides exact clarity to an unbiased set of 15 data imaging points of the abdomen and thorax, including heart and lung (Lisciandro 2011, 2012, 2014, 2020); and should preempt all other POCUS examinations. *The bottom line, POCUS examinations should be considered as an add-on to Global FAST®, or the 2 approaches should be used together to avoid such errors.*

Finally, the Global FAST® Approach, better ensures that more traditional complete ultrasound studies are ordered for the *correct* cavity and that it is safe to restrain the patient especially for dorsal recumbency. The Global FAST® Approach is our 3rd standardized veterinary ultrasound examination, unique because it screens both cavities, and should be a first line extension of the physical exam in most if not all patients (Lisciandro 2020).

Distinguishing Global FAST® from Flashing and POCUS

Global FAST®. Global FAST® is the combination of AFAST® and its Target-organ Approach and its Abdominal Fluid/Hemorrhage Scoring System and urinary bladder volume estimation formula, TFAST® for the detection of pleural and pericardial effusion, pneumothorax, and its 4 TFAST® echo views, and Vet BLUE®, the veterinary brief lung ultrasound exam, a regional, pattern-based approach with its B-line Scoring System, and its Visual Lung Language. Each of these 3 ultrasound formats has exact clarity to its respective acoustic windows (views) and findings (patient data) are recorded in goal-directed templates. Without this disciplined approach, accurate tracking patients and measuring your overall point-of-care ultrasound program quality is impossible. Moreover, the veterinary radiologist and cardiologist perform their studies in the exact same manner every time for good reasons, to better know where to expect anatomy, and better recognize deviations from what is expected, and thus to minimize missing abnormalities. The Global FAST® sonographer's baseline skill set is to be able to recognize free fluid and merely deviations from the expected at its respective target-organs.

Flash exams. The "Flash Approach" is a term applied to a desultory sweep (no organized direction, no defined acoustic windows, no clarity) of the abdomen, thorax, and now lung answering a simple binary question of fluid positive or fluid negative within the abdomen and thorax; and the presence or absence of B-lines (also called lung rockets). The "Flash mentality" should be likened to performing an incomplete physical examination. For most veterinarians, we know the risk of missing important clinical information by doing so.

Point-of-care Ultrasound (POCUS). Point-of-care ultrasound (POCUS), which includes FAST (focused assessment with sonography for trauma, triage and tracking) examinations, is defined by the author as a goal-directed ultrasound examination(s) performed by a healthcare provider point-of-care (cageside) to answer a specific diagnostic question(s) or guide performance of an invasive procedure(s).

**The Global FAST® Approach is not a "Flash exam." AFAST®, TFAST®, Vet BLUE®, and Global FAST® should never be used interchangeably with the "Flash approach." These terms are erroneously and misleadingly used by our colleagues.*

**The Global FAST® Approach should be used as a baseline set of unbiased data imaging points surveying both cavities and then POCUS or Focused Exams as add-on evaluations to prevent "satisfaction of search error", "selective imaging" and "confirmation bias error"; and thus for increasing the probability of an accurate assessment through integration of global clinical findings.*

Patient Positioning, Preparation, Probe Type, Preset, Probe Maneuver

Positioning. Standing (sternal) and lateral recumbency are used. Right lateral recumbency is preferred over left lateral because of it is advantageous for echocardiography, electrocardiography, and imaging the caudal vena cava, however, the fluid scoring system is validated in *either* lateral positioning. Generally, if a patient is standing, AFAST® and Global FAST® are performed in standing. In AFAST®- negative for fluid standing (sternal) patients, lateral recumbency is unnecessary. If AFAST® is positive for free fluid, then follow the "AFAST® 3-minute fluid scoring rule" of moving to lateral recumbency and waiting 3-minutes to allow free fluid to redistribute for an accurate abdominal fluid score. Right lateral recumbency is generally only added to a standing AFAST®- Global FAST® when there is free fluid in the abdomen, TFAST® echo views and characterization of the caudal vena cava and its associated hepatic veins are unsatisfactory, or changes in positioning are warranted to better interrogate target-organs. *Dorsal recumbency is never used because it is too risky for hemodynamically fragile or unstable patients especially with intrathoracic problems including cardiac and pulmonary conditions and pleural space disease.*

Preparation. Fur is not shaved but rather parted with minimal amounts of isopropyl alcohol followed by alcohol-based hand sanitizer (HS) because HS couples as well as commercially available gel with the advantage of evaporating off the patient. Alcohol-based HS is also less noxious and less cooling than isopropyl alcohol; and less gooey (hand sanitizer evaporates) than acoustic coupling gel. Isopropyl alcohol should not be used if electrical defibrillation is anticipated (fire/burn hazard).

**Make every attempt to part the fur and place the probe as directly as possible on skin to maximize the image quality and minimize "air-trapping" between the probe head and the skin.*

Probe Type. The microconvex (curvilinear) probe is used for the entire Global FAST®. A phased-array (sector) cardiac probe and linear probe may be used but each are unnecessary for most patients only adding more time to the study and are generally reserved for more complete detailed examinations.

Preset. The entire AFAST® (and Global FAST®) is performed with the abdominal preset. Preset may be changed, but by doing so, generally only adds time and changing presets may be reserved for more complete detailed examinations. Of note, cardiac presets reverse the orientation used for abdomen and lung, which becomes spatially challenging.

Probe Maneuver. The probe maneuvering is standardized. The probe is fanned, rocked cranially, and returned to the starting point at each AFAST® view. We premise this probe maneuvering on the original study that showed when comparing longitudinal to transverse views, they matched 397/400 times for the detection of free fluid. *All AFAST® views are imaged by fanning, rocking cranially, and returning to the starting point.*

The AFAST®

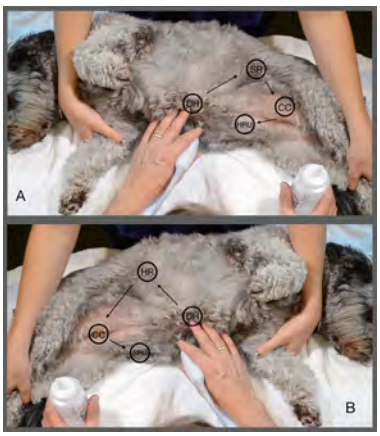

Figure. The AFAST® views used for abdominal fluid scoring are shown on a dog and analogous for cats (and non-human primates and exotic companion mammals). Note not shown is the Hepato-Renal 5th Bonus view

when in right lateral and the Spleno-Renal 5th Bonus view when in left lateral recumbency. *This material is reproduced with permission of John Wiley & Sons, Inc., Point-of-Care Ultrasound Techniques for the Small Animal Practitioner, 2nd Edition, Wiley ©2020 and Greg Lisciandro, Hill Country Veterinary Specialists, FASTVet.com © 2014, 2020.*

AFAST® Order. The AFAST® regardless of positioning (standing/sternal, right lateral recumbency) is always performed in the same order beginning at the Diaphragmatico-Hepatic (DH) view, followed by the least gravity dependent Spleno-Renal (SR) view, then the Cysto-Colic (CC) view, completing the AFAST® at the most gravity dependent Hepato-Renal Umbilical (HRU) view, where abdominocentesis is performed in most fluid-positive patients. The spleen is generally identified in this region (HRU) and then followed performing a Focused Spleen. In left lateral recumbency the order is analogous with the Hepato-Renal (HR) view replacing the Spleno-Renal view and the Spleno-Renal Umbilical (SRU) view replacing the Hepato-Renal Umbilical (HRU) view. As with right lateral recumbency, a Focused Spleen is performed *immediately after the umbilical view* and completing the 4 views of the AFAST® fluid scoring system (DH, SR, CC, HRU).

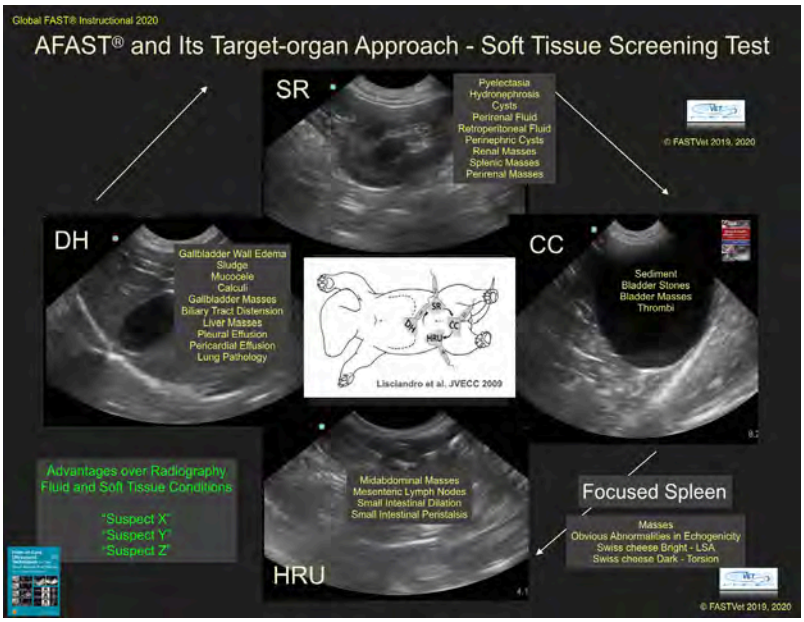

Figure. The AFAST® views used for abdominal fluid scoring are shown on a dog and analogous for cats (and non-human primates and exotic companion mammals) with actual ultrasound images along with obvious soft tissue abnormalities possible. Note not shown is the Hepato-Renal 5th Bonus view when in right lateral and the Spleno-Renal 5th Bonus view when in left lateral recumbency. *This material is reproduced with permission of John Wiley & Sons, Inc., Point-of-Care Ultrasound Techniques for the Small Animal Practitioner, 2nd Edition, Wiley ©2020 and Greg Lisciandro, Hill Country Veterinary Specialists, FASTVet.com © 2014, 2020.*

Diaphragmatico-Hepatic (DH) view. Target-organs are liver, gallbladder and the heart, lung, and pleural cavity looking beyond (cranial to) the diaphragm and the caudal vena cava and its associated hepatic veins as it traverses the diaphragm. They are imaged in longitudinal planes with fanning, rocking cranially, and returning to your starting point.

Soft Tissue Abnormalities Screened for at the DH View:

- Gallbladder sediment and sludge
- Gallbladder mucoceles
- Choleliths

- Gallbladder wall edema
- Gallbladder wall masses
- Biliary tract distension
- Liver masses and cysts
- Liver and heterogenous echogenicity
- Dirofilariasis
- Pericardial effusion
- Pleural effusion
- Lung lesions along the pulmonary-diaphragmatic interface

- **Add-on:** Caudal vena cava characterization (and hepatic venous characterization)

Spleno-Renal (SR) view. Least gravity-dependent view. Target-organs are left kidney and spleen where the spleen is attached to the greater curvature of the stomach via the short gastric vessels. They are imaged in longitudinal planes with fanning, rocking cranially, and returning to your starting point. The stomach and colon are deep to the target-organs and often air-filled shadowing through the far field. This view would be used for the detection of pneumoperitoneum (air would rise).

Soft Tissue Abnormalities Screened for at the SR (and HR) View:

- Retroperitoneal effusion
- Pyelectasia
- Hydronephrosis
- Perirenal fluid
- Perinephric cysts
- Cortical cysts
- Cortical infarction
- Renal masses
- Splenic masses
- Spleen and heterogenous echogenicity
- Perirenal and retroperitoneal masses
- Ureteral distension

- **Add-on:** Pneumoperitoneum and renal perfusion

Cysto-Colic (CC) view. The target-organ is the urinary bladder with the acknowledgement of the colon that when air-filled obscures imaging. Probe (scanning plane) is directed into the view's most gravity-dependent "CC Pouch." They are imaged in longitudinal planes with fanning, rocking cranially, and returning to your starting point. The thigh is often seen through the far field. In predominately intact species, such as non-human primates and exotic companion mammals, the sex organs, especially the uterus, should be part of this view.

Soft Tissue Abnormalities Screened for at the CC View:

- Urinary bladder sediment
- Urinary bladder calculi
- Urinary bladder wall masses
- Urinary bladder thrombi
- Urinary bladder wall irregularities

- Pregnancy
- Uterine abnormalities

Hepato-Renal Umbilical (HRU) view. Most-gravity dependent. Misnomer. The view previously designated Hepato-Renal (HR) view is now considered the "Hepato-Renal Umbilical (HRU) view." Target-organs are really the spleen and intestine. Neither the right kidney nor the right liver is imaged. The probe is placed at the level of the umbilicus and imaged its scanning plane into the most gravity-dependent "HR Umbilical Pouch." In standing or sternal, the probe as placed on the umbilicus. Fanning, rocking cranially, and returning to the starting point is the same probe maneuver at all AFAST® views. In predominately intact species, such as non-human primates and exotic companion mammals, the sex organs, especially the uterus, should be part of this view. This view really should be renamed as the "Spleno-Intestino Umbilical view" (and likely will be).

Soft Tissue Abnormalities Screened for at the HR-Umbilical View:

- Heterogenous echogenicity of the splenic parenchyma
    - Bright Swiss Cheese R/O lymphoma
    - Dark Swiss Cheese R/O splenic torsion
- Splenomegaly
- Myelolipomas
- Splenic masses
- Mid abdominal masses
- Abnormalities of the splenic hilar vessels
- Small intestinal peristalsis
- Pregnancy
- Uterine abnormalities

Hepato-Renal 5th Bonus View: Not part of the abdominal fluid scoring system. Most often performed standing immediately as the final view of Global FAST®. Target-organs are right kidney and adjacent right liver. They are imaged in longitudinal planes with fanning, rocking cranially, and returning to your starting point.

Soft Tissue Abnormalities Screened for at the HR5th Bonus (SR5th Bonus) View:

- Retroperitoneal effusion
- Pyelectasia
- Hydronephrosis
- Perirenal fluid
- Perinephric cysts
- Cortical cysts
- Cortical infarction
- Renal masses
- Liver masses
- Liver and heterogenous echogenicity
- Perirenal and retroperitoneal masses
- Ureteral distension

- **Add-on:** Portal vein interrogation, pancreas, duodenum

GOAL-DIRECTED TEMPLATE FOR AFAST®

Patient positioning: right or left lateral recumbency or standing or sternal
Gallbladder: present or absent, contour, wall, content, unremarkable or abnormal
Urinary bladder: present or absent, contour, wall, content, unremarkable or abnormal

Positive of negative at the 4-views (0 negative, 1 positive)

Diaphragmatico-Hepatic (DH) site:	0 or 1/2 or 1
Spleno-Renal (SR) site:	0 or 1/2 or 1
Cysto-Colic (CC) site:	0 or 1/2 or 1
Hepato-Renal Umbilical (HRU) site:	0 or 1/2 or 1

Total Abdominal Fluid Score (0-4): _____

HR5th Bonus View: 0 or 1/2 or 1 **or Indeterminate or Not Assessed (NA)**
Focused Spleen (*add-on after completing the* AFAST® HR Umbilical View): _____

DH View:
Pleural effusion: absent, present (mild, moderate, severe) or indeterminate or NA
Pericardial effusion: absent, present (mild, moderate, severe) or indeterminate or NA
[$]**Hepatic venous distension:** unremarkable or present (Tree Trunk Sign) or indeterminate or NA
[&]**Caudal vena cava characterization:** bounce (unremarkable) or FAT or flat or indeterminate or NA
[#]**Vet BLUE:** B-lines: 0, 1, 2, 3, >3, or ∞ and if Shred__cm, Tissue__cm, Nodule__cm, Wedge__cm

Comments:_____
Note: The AFAST® is a rapid ultrasound examination used to detect the presence of free abdominal fluid and obvious soft tissue abnormalities as a screening test in order to better direct resuscitation efforts and diagnostics, detect complications, and manage patients. AFAST® is not intended to replace a complete detailed abdominal ultrasound exam.

[$]**The hepatic veins** should *not* be apparent in both dogs and cats placed in lateral recumbency. When imaged the branching has been referred to by the author as the "Tree Trunk Sign."
[&]**The caudal vena cava** can be alternatively referred to as a bounce = fluid responsive cava (~35-50% diameter change); FAT = fluid intolerant cava (distended with maximum height > 1 cm in dogs < 9kg and > 1.5 cm in dogs > 9kg with little height change [< 10%]); flat = hypovolemic cava (small with maximum height < 3 mm in dogs < 9 kg, < 5 mm in dogs > 9 kg with little height change [< 10%]).
[#]**Vet BLUE** screens for lung abnormalities along the Pulmonary-Diaphragmatic Interface.

Template provided by Dr. Gregory Lisciandro, DVM, DABVP, DACVECC, FASTVet.com and Hill Country Veterinary Specialists Copyright 2018, 2019, 2020 for your use and modification.

Other current Goal-directed Template AFAST®, TFAST®, Vet BLUE® and Global FAST® versions may be found at FASTVet.com under the Premium Membership, then Resource Library, and then Free Resources.

AFAST® Add-on Information
AFAST® can answer many clinical questions within its 5-view framework. Add-on skills include the following:

- The AFAST® Cysto-Colic View urinary bladder volume estimation formula (LxHxWx0.625) to estimate urine volume and thus over time non-invasively estimate urine output (Lisciandro and Fosgate 2017)
- Pneumoperitoneum (Enhanced Peritoneal Stripe Sign)

- Gastrointestinal peristalsis
- Renal perfusion
- Volume status via characterization of the caudal vena cava and hepatic veins – *See Global FAST® Proceedings*
- Intrathoracic abnormalities especially pleural and pericardial effusion and lung abnormalities along the pulmonary-diaphragmatic interface - *See TFAST® Proceedings*

References & Further Reading

1. **Lisciandro GR**, Lagutchik MS, Mann KA, et al. Evaluation of an abdominal fluid scoring system determined using abdominal focused assessment with sonography for trauma (AFAST) in 101 dogs with motor vehicle trauma. *J Vet Emerg Crit Care* 2009; 19(5):426-437.
2. Boysen SR, Rozanski EA, Tidwell AS, et al. Evaluation of a focused assessment with sonography for trauma protocol to detect free abdominal fluid in dogs involved in motor vehicle accidents. *J Am Vet Med Assoc* 2004; 225(8):1198-1204.
3. **Lisciandro GR**. Focused abdominal (AFAST) and thoracic (TFAST) focused assessment with sonography for trauma, triage and monitoring in small animals. *J Vet Emerg Crit Care* 2011;20(2):104-122 .
4. **Lisciandro GR**. Chapters 2: The Abdominal (AFAST) Exam; Chapter 16: Focused or COAST^3 - CPR, Global FAST and FAST ABCDE. *In* Focused Ultrasound for the Small Animal Practitioner, Editor, Lisciandro GR. Wiley Blackwell: Ames IA 2014.
5. **Lisciandro GR**. Chapter 55: Ultrasound in Animals. *In* Critical Care Ultrasound (human textbook), Editors Lumb and Karakitsos. Elsevier: St. Louis, MO 2014.
6. **Lisciandro GR**. Evaluation of initial and serial combination focused assessment with sonography for trauma (CFAST) examination of the thorax (TFAST) and abdomen (AFAST) with the application of an abdominal fluid scoring system in 49 traumatized cats. *J Vet Emerg Crit Care* 2012;22(2):S11.
7. **Lisciandro GR**. Lisciandro GR. The use of the diaphragmatico-hepatic (DH) view of the abdominal and thoracic focused ultrasound techniques with sonography for triage (AFAST/TFAST) examinations for the detection of pericardial effusion in 24 dogs (2011-2012). *J Vet Emerg Crit Care* 2016;26(1):125-31.
8. **Lisciandro, GR**. Alanine aminotransferase level (ALT) as a marker for hemoabdomen detected by abdominal FAST (AFAST) in dogs with automobile trauma. *Abstract, J Vet Emerg Crit Care,* 2014; 24(S1):S11.
9. McMurray J, Boysen S, Chalhoub S. Focused Assessment with Sonography in Non-trauma dogs and cats in the emergency and critical care setting. Abstract. *J Vet Emerg Crit Care,* 2014; 24(S1):S28.
10. **Lisciandro GR**. Abdominal FAST (AFAST)-detected Hemorrhagic Abdominal Effusion in 11 Dogs with Acute Collapse and Gallbladder Wall Edema (Halo Sign) with Presumed Anaphylaxis. *Abstract, J Vet Emerg Crit Care 2016.*
11. **Lisciandro GR**. Alanine aminotransferase level (ALT) as a marker for hemoabdomen detected by abdominal FAST (AFAST) in dogs with automobile trauma. *Abstract, J Vet Emerg Crit Care, 2014.*
12. Hnatusko Al, Gicking JC, **Lisciandro GR**. Anaphylaxis-related hemoperitoneum in 11 dogs. *J Vet Emerg Crit Care, In Press 2019.*
13. **Lisciandro GR**, Fosgate GT, Romero LA, et al. The Expected Frequency and Amount of Free Peritoneal Fluid Estimated Using the Abdominal FAST-applied Abdominal Fluid Scores in Clinically Normal Adult and Juvenile Dogs. *J Vet Emerg Crit Care, In Press* 2019.
14. Higgs VA, Rudloff E, Kirby R, et al. Autologous blood transfusion in dogs with thoracic or abdominal hemorrhage: 25 cases. *J Vet Emerg Crit Care* 2015; 25(6): 731-738.
15. Cole LP, Humm K. Twelve autologous blood transfusions in eight cats with hemoperitoenum. *J Feline Med Surg* 2018; Jul 1:1098612X18785742. doi: 10.1177/1098612X18785742. [Epub ahead of print].
16. Robinson DA, Kiefer K, Bassett R, et al. Autotransfusion in dogs using a 2-syringe technique. *J Vet Emerg Crit Care* 2016; 26(6): 766-774.

17. Narasimhan M, Koenig SJ, Mayo PH. A Whole-Body Approach to Point of Care Ultrasound. *Chest* 2016; 150(4): 772-776.
18. Culp WT, Weisse C, Kellog ME, et al. Spontaneous hemopertoneum in cats: 65 cases (1994-2006). J Am Vet Med Assoc 2010; 236(9): 978-982.
19. **Lisciandro GR**. Chapter 3: Point-of-care Ultrasound. *In:* Small Animal Diagnostic Ultrasound, 4th Edition, edited by Mattoon JS, Sellon RK, and Berry CR. Elsevier: St. Louis, MO, *In Press* 2019.

AFAST®and Its Abdominal Fluid Scoring System for Bleeding Patients – Everyday Extension of Your Physical Exam

Emerald Coast Veterinary Conference, Sandestin, FL, USA
Gregory R. Lisciandro, DVM, Dipl. ABVP, Dipl. ACVECC
Hill Country Veterinary Specialists & FASTVet.com, Spicewood, Texas USA
Email LearnGlobalFAST@gmail.com
Cell 210.260.5576
Website FASTVet.com

Textbook Point-of-care Ultrasound Techniques for the Small Animal Practitioner, 2nd Edition, Wiley ©2021

The AFAST®

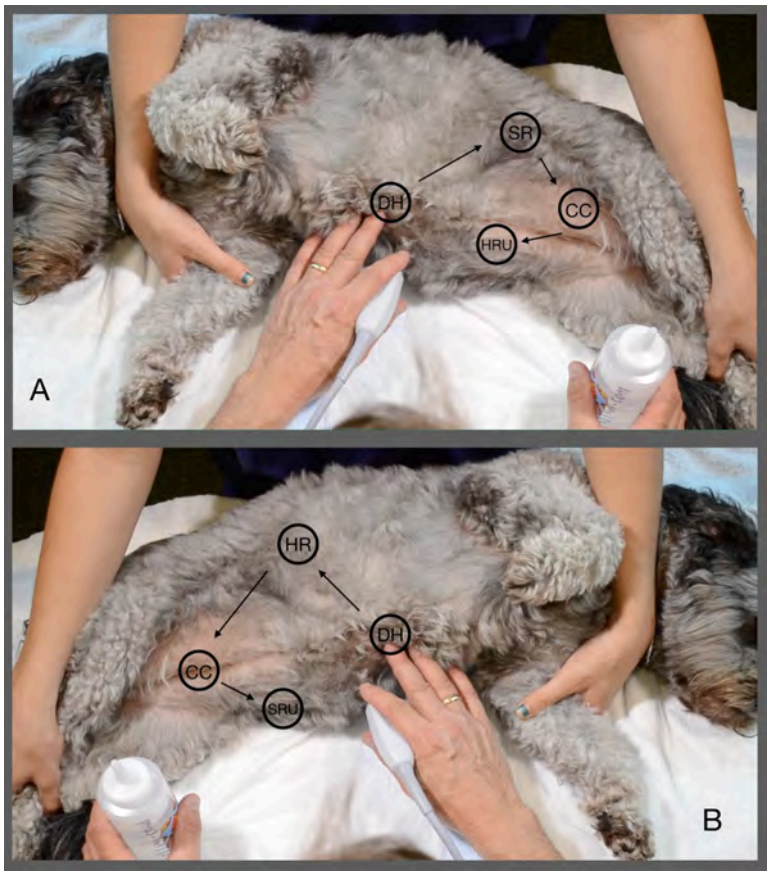

Figure. The AFAST® views used for abdominal fluid scoring are shown on a dog and analogous for cats (and non-human primates and exotic companion mammals). Note *not shown* is the Hepato-Renal 5th Bonus view when in right lateral and the Spleno-Renal 5th Bonus view when in left lateral recumbency. *This material is reproduced with permission of John Wiley & Sons, Inc, Focused Ultrasound Techniques for the Small Animal Practitioner, Wiley ©2014 and Gregory Lisciandro, DVM, FASTVet.com ©2020.*

Patient Positioning, Preparation, Probe Type, Preset, Probe Maneuver

Positioning. *See Proceedings entitled AFAST® Introduction and Its Target Organ Approach – Everyday Extension of Your Physical Exam*

AFAST® Order and Views. *See Proceedings entitled AFAST® Introduction and Its Target Organ Approach – Everyday Extension of Your Physical Exam*

AFAST®-Applied Fluid Scoring System

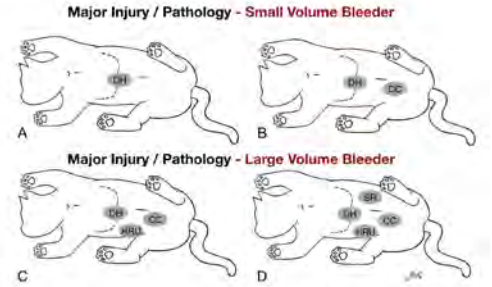

The AFAST®-applied fluid scoring system is defined as follows (4-point scale): abdominal fluid score (AFS) of 0 (AFS 0) means negative at all 4 views to a maximum score of AFS 4 means positive at all 4 views.

*Low-scoring AFS1 and 2 (<3) are considered major injury/pathology, small volume bleeders.
*High-scoring AFS 3 and 4 (≥3) are considered major injury/pathology, large volume bleeders.
Modified from Lisciandro, et al. JVECC 2009; 19(5): 426-437, JVECC 2011;20(2); 104-122. *Gregory Lisciandro, FASTVet.com, Wiley ©2020.*

This material is reproduced with permission of John Wiley & Sons, Inc., Point-of-Care Ultrasound Techniques for the Small Animal Practitioner, 2nd Edition, Wiley ©2020 and Greg Lisciandro, Hill Country Veterinary Specialists, FASTVet.com © 2014, 2020.

The AFAST®-applied is hugely impactful and should be assigned and recorded in every patient. It's a simple 0-4 scoring system and has significant advantages over subjective terms of trivial, mild, moderate and severe as well as designating each respective positive and negative AFAST® view. Recording positive and negative views may help with origin of bleeding or effusion (peritonitis) in lower-scoring patients. For example, in a bleeding trauma patient that has an AFS of 1 and positive at the DH view, that over time becomes a large volume bleeder with an AFS ≥ 3, logic would dictate the source of bleeding is likely the liver and/or its associated vasculature.

Small versus Large Volume Bleeder/Effusion. The abdominal fluid score (AFS) helps rapidly categorize the patient as a small volume (AFS 1 and 2, or < 3) versus large volume bleeder (AFS 3 and 4, or ≥ 3). AFS 1 and 2 (< 3) do not have enough blood intra-abdominal to directly result in anemia. Thus, if an AFS 1 or 2 is anemic, then there are the following 4 major rule outs in the acute setting: 1) preexisting anemia, 2) bleeding somewhere else - always do Global FAST® and a good physical exam, 3) hemodilution (less common with graduated fluid therapy strategies), or 4) lab error. The AFS allows tracking of worsening (increasing AFS), resolving (decreasing AFS), or static (no change in AFS). Patients also become volume depleted from non-hemorrhagic effusions and thus small versus large volume effusion principle works for anticipating hypovolemia from fluid loss (without the need for hemoglobin).

Modification of the Abdominal Fluid Scoring System - 0 or 1/2 or 1

Scoring as 0, ½, or 1. The author for several years has been categorizing positives as "weak" if the maximum pocket is <1 cm (<5 mm in cats) scoring as a "1/2" versus a "strong" positive if >1 cm (>5 mm in cats) making the score a full "1." The small vs. large volume bleeding concept remains as AFS 1 and 2 small volume (< 3), and AFS 3 and 4 (≥ 3), large volume bleeders. Clinical judgment always should be considered; however, this "weak" versus "strong" positive modification provides an option to better assess and semi-quantitate volume in bleeding patients and those with other forms of ascites and peritonitis. The modification of our original scoring system is based on a recently accepted study and an ongoing project (Lisciandro et al. 2020).

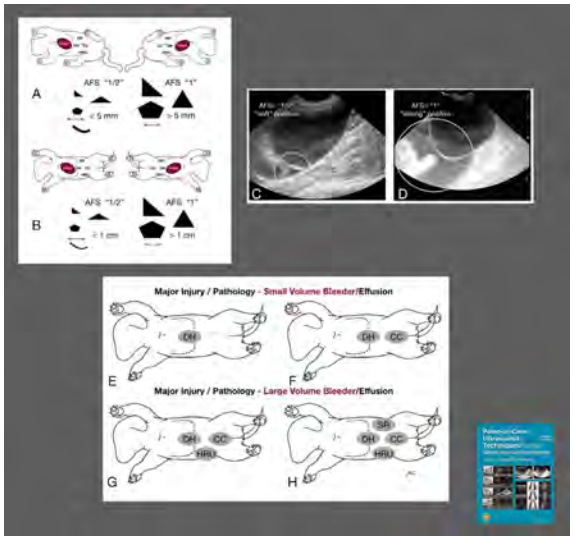

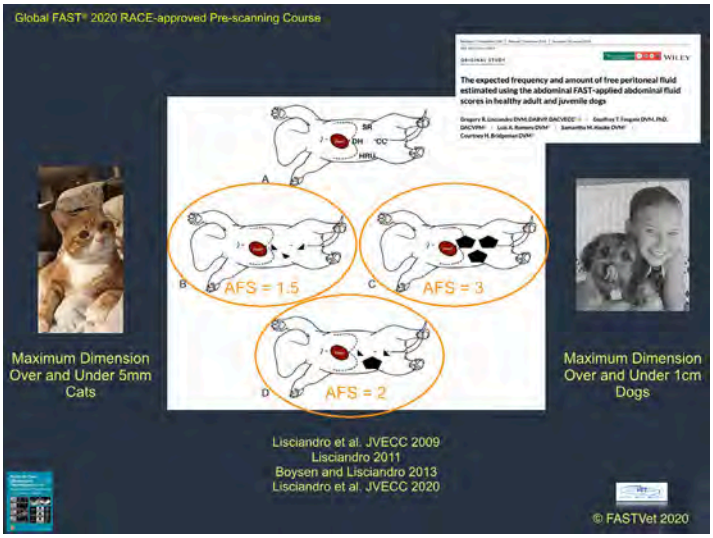

Figure on Left. A cartoon of a cat and dog in lateral recumbency showing the modification of the abdominal fluid score (AFS) to better differentiate between small volume versus large volume bleeding/effusion by assigning a score of "1/2" or "1" for "weak" versus "strong" positive views, respectively.

Figure on Right. For example, a dog may have small pockets at the DH, CC, and HRU views of <1 cm, that would now be considered more accurately a small volume bleeder/effusion with a score of ½ + ½ + ½ = "1 1/2" in B) rather than a 1 + 1+ 1 = "3" in C). Note in D) the score is ½ + ½ + 1 for a total of "2." This approach may also be translated to non-human primates and exotic companion mammals. *This material is reproduced with permission of John Wiley & Sons, Inc., Point-of-Care Ultrasound Techniques for the Small Animal Practitioner, 2nd Edition, Wiley ©2020 and Greg Lisciandro, Hill Country Veterinary Specialists, FASTVet.com © 2014, 2020.*

Use of Serial AFAST® and Determining the AFS

The use of serial AFAST® and serial application of its abdominal fluid scoring system is imperative to maximize information. The serial exam not only improves the sensitivity of the exam (true negatives) but also searches a second time for the developing presence of fluid, tracking the abdominal fluid score (0-4), and evaluating the presence or absence of the urinary bladder, and measuring the urinary bladder dimensions for estimating its volume. Always perform one more 4-hour post-admission serial AFAST® (better Global FAST®) in all stable patients and sooner if the patient is unstable or of questionable status. Then continue serial AFAST® (better Global FAST®) as needed and as part of patient rounds and recheck exams.

Hemoabdomen

***Trauma**. Use small versus large volume bleeder principle for anticipating degree of anemia from the intra-abdominal hemorrhage. Most dogs and cats are treated medically through the use of titrated fluid therapy, blood transfusions, and correction of coagulopathy when present with surgery uncommonly needed.

***Non-trauma.** Use small volume versus large volume bleeder principle. Transfusion needs may be anticipated for a component of supportive care (and correcting coagulopathy when present) in coordination with surgical treatment and other possible interventions for stopping bleeding masses. Canine anaphylactic hemoabdomen is a species-unique, medically treated (not surgical) complication of dogs; and its coagulopathy treated when present. See Canine Anaphylactic Webinar off our website FASTVet.com and our most updated Canine Anaphylactic Proceedings.

***Post-interventional.** Use small volume versus large volume bleeder principle. As a general rule, large volume bleeders should be surgically treated when, if present, coagulopathy is first corrected and coagulopathy not the direct cause for the bleeding. Blood may be harvested from clean cavities in both dogs and cats and re-administered to the patient without anticoagulant but with a mandatory blood filter to catch clots from entering the patient's circulation.

AFAST®-applied Abdominal Fluid Scoring for Non-hemorrhagic Ascites

The small volume versus large volume effusion principle serves a similar role for predicting degree of hypovolemia keeping in mind that for example patients can become markedly volume contracted from a septic peritonitis. The difference in non-hemorrhagic effusions is that volume needs to be restored but without the need for hemoglobin unless the patient is anemic for another reason.

Expectations for Resolution of Hemoabdomen and Lavage Fluid

FASTVet 48-hour Rule. Expect cavitary bleeding to be resolved or nearly resolved within 48-hours with near negative abdominal fluid scores of AFS ≤ 1 (resorption of blood by the patient) once bleeding has stopped and coagulopathy, when present, is corrected. When positive fluid scores persist, especially large volume bleeders, then the cause must be investigated further because a major problem, i.e. active bleeding or coagulopathy, is present until proven otherwise. Of note, post-interventional cases should have their abdominal cavity free of fluid at surgical closure when possible, so that positive post-interventional fluid scores may be better interpreted. From author experience and most interestingly, lavage fluid lasts much longer than 48-hours in contrast to blood, and also inhibits neutrophil function in fighting peritonitis. *Thus, lavage fluid should always be as completely removed as possible before surgical closure because it persists for several days unlike blood.*

Radiographic Serosal Detail is Unreliable

Radiographic serosal detail been shown to be unreliable for not only the detection of ascites but also its amount in both human and veterinary imaging. In our original study, we found that 24% of dogs with normal radiographic serosal detail were in fact positive for free intra-abdominal fluid (abdominal fluid score, AFS, 1-4), and 33% with decreased serosal detail were in fact negative for free intra-abdominal fluid (AFS 0). The use of the AFAST®- abdominal fluid scoring system is evidence-based by "seeing" and scoring its volume comparable to the gold standard test of computed tomography.

Clinical Indications for AFAST®

The use of AFAST® should be simply stated as an "extension of the physical exam" in other words everyday applications for nearly every patient. *Global FAST® should be your first line "free fluid and soft tissue screening test" because it exceeds the yield radiographically in the great majority of our patients; and be as part of a work-up as blood and urine testing.* Think about long list of effusive and soft tissue conditions missed or only suspected by radiography that are detected and evidence-based using the AFAST® target-organ approach. *See Proceedings entitled AFAST® Introduction and Its Target Organ Approach – Everyday Extension of Your Physical Exam*

In summary, AFAST® is an" extension of the physical exam" and used for triaged trauma, non-trauma and post-interventional cases, your pre-anesthetic test, your semi-annual and annual checkup, your geriatric screening test, part of patient rounds and recheck exams, and for surveying patients with shock and part of basic and advanced life support in cardiopulmonary resuscitation.

GOAL-DIRECTED TEMPLATE FOR AFAST®

Patient positioning: right or left lateral recumbency or standing or sternal
Gallbladder: present or absent, contour, wall, content, unremarkable or abnormal
Urinary bladder: present or absent, contour, wall, content, unremarkable or abnormal

Positive of negative at the 4-views (0 negative, 1 positive)

Diaphragmatico-Hepatic (DH) site:	0 or 1/2 or 1
Spleno-Renal (SR) site:	0 or 1/2 or 1
Cysto-Colic (CC) site:	0 or 1/2 or 1
Hepato-Renal Umbilical (HRU) site:	0 or 1/2 or 1

Total Abdominal Fluid Score (0-4): _____

HR5th Bonus View: 0 or 1/2 or 1 **or Indeterminate or Not Assessed (NA)**
Focused Spleen (*add-on after completing the* AFAST® HR Umbilical View): **_____**

DH View:
Pleural effusion: absent, present (mild, moderate, severe) or indeterminate or NA
Pericardial effusion: absent, present (mild, moderate, severe) or indeterminate or NA
[$]**Hepatic venous distension:** unremarkable or present (Tree Trunk Sign) or indeterminate or NA
[&]**Caudal vena cava characterization:** bounce (unremarkable) or FAT or flat or indeterminate or NA
[#]**Vet BLUE®:** B-lines: 0, 1, 2, 3, >3, or ∞ and if Shred__cm, Tissue__cm, Nodule__cm, Wedge__cm

Comments:_____
Note: The AFAST® is a rapid ultrasound examination used to detect the presence of free abdominal fluid and obvious soft tissue abnormalities as a screening test in order to better direct resuscitation efforts and diagnostics, detect complications, and manage patients. AFAST® is not intended to replace a complete detailed abdominal ultrasound exam.

[$]**The hepatic veins** should *not* be apparent in both dogs and cats placed in lateral recumbency. When imaged the branching has been referred to by the author as the "Tree Trunk Sign."
[&]**The caudal vena cava** can be alternatively referred to as a bounce = fluid responsive cava (~35-50% diameter change); FAT = fluid intolerant cava (distended with maximum height > 1 cm in dogs < 9kg and > 1.5 cm in dogs > 9kg with little height change [< 10%]); flat = hypovolemic cava (small with maximum height < 3 mm in dogs < 9 kg, < 5 mm in dogs > 9 kg with little height change [< 10%]).
[#]**Vet BLUE®** screens for lung abnormalities along the Pulmonary-Diaphragmatic Interface.

Template provided by Dr. Gregory Lisciandro, DVM, DABVP, DACVECC, FASTVet.com and Hill Country Veterinary Specialists Copyright 2018, 2019, 2020 for your use and modification.

Other current Goal-directed Template AFAST®, TFAST®, Vet BLUE® and Global FAST® versions may be found at FASTVet.com under the Premium Membership, then Resource Library, and then Free Resources.

References & Further Reading

1. **Lisciandro GR**, Lagutchik MS, Mann KA, et al. Evaluation of an abdominal fluid scoring system determined using abdominal focused assessment with sonography for trauma (AFAST) in 101 dogs with motor vehicle trauma. *J Vet Emerg Crit Care* 2009; 19(5):426-437.
2. Boysen SR, Rozanski EA, Tidwell AS, et al. Evaluation of a focused assessment with sonography for trauma protocol to detect free abdominal fluid in dogs involved in motor vehicle accidents. *J Am Vet Med Assoc* 2004; 225(8):1198-1204.
3. **Lisciandro GR**. Focused abdominal (AFAST) and thoracic (TFAST) focused assessment with sonography for trauma, triage and monitoring in small animals. *J Vet Emerg Crit Care* 2011;20(2):104-122 .
4. **Lisciandro GR**. Chapters 2: The Abdominal (AFAST) Exam; Chapter 16: Focused or COAST^3 - CPR, Global FAST and FAST ABCDE. *In* Focused Ultrasound for the Small Animal Practitioner, Editor, Lisciandro GR. Wiley Blackwell: Ames IA 2014.
5. **Lisciandro GR**. Chapter 55: Ultrasound in Animals. *In* Critical Care Ultrasound (human textbook), Editors Lumb and Karakitsos. Elsevier: St. Louis, MO 2014.
6. **Lisciandro GR**. Evaluation of initial and serial combination focused assessment with sonography for trauma (CFAST) examination of the thorax (TFAST) and abdomen (AFAST) with the application of an abdominal fluid scoring system in 49 traumatized cats. *J Vet Emerg Crit Care* 2012;22(2):S11.
7. **Lisciandro GR**. Lisciandro GR. The use of the diaphragmatico-hepatic (DH) view of the abdominal and thoracic focused ultrasound techniques with sonography for triage (AFAST/TFAST) examinations for the detection of pericardial effusion in 24 dogs (2011-2012). *J Vet Emerg Crit Care* 2016;26(1):125-31.
8. **Lisciandro, GR**. Alanine aminotransferase level (ALT) as a marker for hemoabdomen detected by abdominal FAST (AFAST) in dogs with automobile trauma. *Abstract, J Vet Emerg Crit Care,* 2014; 24(S1):S11.
9. McMurray J, Boysen S, Chalhoub S. Focused Assessment with Sonography in Non-trauma dogs and cats in the emergency and critical care setting. Abstract. *J Vet Emerg Crit Care,* 2014; 24(S1):S28.
10. **Lisciandro GR**. Abdominal FAST (AFAST)-detected Hemorrhagic Abdominal Effusion in 11 Dogs with Acute Collapse and Gallbladder Wall Edema (Halo Sign) with Presumed Anaphylaxis. *Abstract, J Vet Emerg Crit Care 2016.*
11. **Lisciandro GR**. Alanine aminotransferase level (ALT) as a marker for hemoabdomen detected by abdominal FAST (AFAST) in dogs with automobile trauma. *Abstract, J Vet Emerg Crit Care, 2014.*
12. Hnatusko Al, Gicking JC, **Lisciandro GR**. Anaphylaxis-related hemoperitoneum in 11 dogs. *J Vet Emerg Crit Care, In Press 2019.*
13. **Lisciandro GR**, Fosgate GT, Romero LA, et al. The Expected Frequency and Amount of Free Peritoneal Fluid Estimated Using the Abdominal FAST-applied Abdominal Fluid Scores in Clinically Normal Adult and Juvenile Dogs. *J Vet Emerg Crit Care, In Press* 2019.
14. Higgs VA, Rudloff E, Kirby R, et al. Autologous blood transfusion in dogs with thoracic or abdominal hemorrhage: 25 cases. *J Vet Emerg Crit Care* 2015; 25(6): 731-738.
15. Cole LP, Humm K. Twelve autologous blood transfusions in eight cats with hemoperitoenum. *J Feline Med Surg* 2018; Jul 1:1098612X18785742. doi: 10.1177/1098612X18785742. [Epub ahead of print].
16. Robinson DA, Kiefer K, Bassett R, et al. Autotransfusion in dogs using a 2-syringe technique. *J Vet Emerg Crit Care* 2016; 26(6): 766-774.
17. Narasimhan M, Koenig SJ, Mayo PH. A Whole-Body Approach to Point of Care Ultrasound. *Chest* 2016; 150(4): 772-776.
18. Culp WT, Weisse C, Kellog ME, et al. Spontaneous hemopertoneum in cats: 65 cases (1994-2006). J Am Vet Med Assoc 2010; 236(9): 978-982.
19. **Lisciandro GR**. Chapter 3: Point-of-care Ultrasound. *In:* Small Animal Diagnostic Ultrasound, 4th Edition, edited by Mattoon JS, Sellon RK, and Berry CR. Elsevier: St. Louis, MO, *In Press* 2019.

TFAST® for the Accurate Diagnosis of Pleural Pericardial Effusion – Everyday Extension of Your Physical Exam

Emerald Coast Veterinary Conference, Sandestin, FL, USA
Gregory R. Lisciandro, DVM, Dipl. ABVP, Dipl. ACVECC
Hill Country Veterinary Specialists & FASTVet.com, Spicewood, Texas USA
Email LearnGlobalFAST@gmail.com
Cell 210.260.5576
Website FASTVet.com

Textbook Point-of-care Ultrasound Techniques for the Small Animal Practitioner, 2nd Edition, Wiley

©2021

Introduction

The clinical utility of TFAST®, its use for the rapid detection of pneumothorax, pleural and pericardial effusion, and its target-organ approach for the heart, will be reviewed. The previously published T^3 designation was meant to include Trauma, Triage (non-trauma), and Tracking (monitoring) to avoid the confusing acronyms in human and now veterinary medicine, in which similar FAST ultrasound examinations are given different acronyms and names for different subsets of patients. However, TFAST®, as with Global FAST®, is best now considered as "an extension of the physical examination" and the T^3 designation is unnecessary as more and more veterinarians understand its widespread applications. Moreover, TFAST® is standardized and has *exact* clarity to its 5-acoustic windows or views. The TFAST® carries greater potential to positively guide clinical course and improve patient outcome by detecting conditions and complications otherwise missed or delayed based on traditional first line evaluations of physical examination, laboratory testing, and radiographic finding. TFAST® findings are made more clinically relevant for the clinician, client, and referring veterinarian by using its standardized format, and by recording TFAST® findings on standardized goal-directed templates for medical records (see below). The mindset for those using TFAST® is one of a *ruling in* and *ruling out* test (highly specific and highly sensitive) for pleural or pericardial effusion, and for pneumothorax. TFAST® also serves as a *ruling in* test for soft tissue abnormalities of its target-organ, the heart (specific but variably sensitive [user dependent]). Meaning, if you see an abnormality, it's likely real, however, if you don't see an abnormality, then it may have been missed since we are not trained like a cardiologist or radiologist. Importantly, the TFAST® does not replace complete detailed echocardiography.

The standardization and clarity of Global FAST®, the term used for combining AFAST®, TFAST® and Vet BLUE®, is the author's recommended approach for using point-of-care ultrasound (POCUS) because it avoids "selective imaging" and "satisfaction of search error." "Selective imaging" leads to "confirmation bias error", searching for evidence to fulfill the clinician's preconceived bias for the diagnosis. "Satisfaction of search error" is a common error in radiology and occurs when the evaluator stops the exam at the first abnormality carrying the potential to miss other important findings. Advantageously, the Global FAST® Approach provides exact clarity to an unbiased set of 15 data imaging points of the abdomen and thorax, including heart and lung; and should preempt all other POCUS examinations. *The bottom line, POCUS examinations should be considered as an add-on to Global FAST®, or the 2 approaches should be used together to avoid such imaging errors.* The Global FAST® Approach is our 3rd standardized veterinary ultrasound examination, unique in that it screens both cavities, in addition to complete detailed abdominal ultrasound and complete echocardiography. Global FAST® including TFAST® should be used as a first line "extension of the physical exam" in most if not all patients.

Distinguishing Global FAST® from Flashing and POCUS

Flash exams. The "Flash Approach" is a term applied to a desultory sweep (no organized direction, no defined acoustic windows, no clarity) of the abdomen, thorax, and now lung answering a simple binary question of fluid positive or fluid negative within the abdomen and thorax; and the presence or absence of B-lines (also called lung rockets). The "Flash mentality" should be likened to performing an incomplete physical examination and for most veterinarians we know the risk of missing important clinical information by doing so. *AFAST®, TFAST®, Vet BLUE®, and Global FAST® should never be used interchangeably with the "Flash approach." These terms have been and continue to be erroneously and misleadingly used by some of our colleagues.*

Point-of-care Ultrasound (POCUS). Point-of-care ultrasound (POCUS), which includes FAST (focused assessment with sonography for trauma, triage and tracking) examinations, is defined by the author as a goal-directed ultrasound examination(s) performed by a healthcare provider point-of-care (cageside) to answer a specific diagnostic question(s) or guide performance of an invasive procedure(s). *The Global FAST® Approach should be used as a baseline set of unbiased data imaging points surveying both cavities and then POCUS or Focused Exams as add-on evaluations to prevent "selective imaging" and "confirmation bias error", "satisfaction of search error", and for increasing the probability of an accurate assessment through integration of clinical findings.*

Patient Positioning, Preparation, Probe Type, Preset, Probe Maneuver

Positioning. Standing (sternal) and lateral recumbency are used. Standing and sternal are generally safer for respiratory compromised or distressed patients. However, patients that are stable and confortable in lateral recumbency may be evaluated in that position as well. Right lateral recumbency is preferred over left lateral because of it is advantageous for echocardiography, electrocardiography, and imaging the caudal vena cava, however, the AFAST® abdominal fluid scoring system is validated in either lateral positioning. Generally, if a patient is standing, TFAST® and Vet BLUE® are first performed from the left side followed by AFAST® and a Focused Spleen after which a right Vet BLUE®, TFAST® echo views and the HR5th Bonus view of AFAST® are performed on the patient's right side. The order is referred to as the Global FAST® blend and is low impact for the patient requiring minimal restraint and patient risk if hemodynamically fragile. Regarding AFAST®, if the patient is AFAST®-negative in standing (or sternal), then lateral recumbency is unnecessary. If the patient is AFAST®-positive, then follow the "AFAST® 3-minute fluid scoring rule" of moving to lateral recumbency when safe, and waiting 3-minutes to allow free fluid to redistribute for an accurate abdominal fluid score. Right lateral recumbency is generally only added to a standing AFAST®- Global FAST® when TFAST® echo views and characterization of the caudal vena cava and its associated hepatic veins are unsatisfactory, or changes in positioning are warranted to better interrogate target-organs. *Dorsal recumbency is never used because it is too risky for hemodynamically fragile or unstable patients especially with intrathoracic problems including cardiac and pulmonary conditions and pleural space disease.*

Preparation. Fur is not shaved but rather parted with minimal amounts of isopropyl alcohol followed by alcohol-based hand sanitizer because it couples as well as commercially available gel with the advantage of evaporating off the patient. *Make every attempt to part the fur and place the probe as directly as possible on skin to maximize the image quality and minimize "air-trapping" between the probe head and the skin.*

Probe Type. The microconvex (curvilinear) probe is used for the entire Global FAST®. A phased-array (sector) cardiac probe and linear probe may be used but each are unnecessary, only adding more time to the examination, and are generally reserved for more complete detailed examinations.

Preset. The TFAST® and entire Global FAST® are performed with the abdominal preset. Changing the preset is unnecessary and only adds time, reserved for more complete detailed examinations.

Probe Maneuver. The probe maneuvering is standardized for lung and cardiac views. Lung begins with the Gator Sign orientation and maintaining longitudinal planes. The left Pericardial Site View has the "TFAST® slide" cranial and caudal to the heart into pouches named the cardiac-diaphragmatic and cardiac-cervical pouch, respectively.

The TFAST®

Strengths and Weaknesses of the TFAST® Views

There are 5 acoustic windows for TFAST®. These are the bilaterally applied Chest Tube Site and Pericardial Site views, and the singly applied Diaphragmatico-Hepatic view. As an aside, the CTS site view followed by Vet BLUE® are performed first, followed by the Pericardial Site views on both the left and right side.

Pneumothorax - Chest Tube Site (CTS) views. The bilaterally applied CTS view is best used to rule out pneumothorax (PTX) and survey for lung pathology (see Vet BLUE Proceedings) on both the left and right sides. The CTS view is along the highest accessible locations on the thoracic wall where the free air within the pleural cavity would rise to in the presence of PTX. Thus, if lung is observed in direct opposition to the thoracic wall at the CTS view, most commonly by "lung sliding" or B-lines, then PTX is ruled out. When PTX is suspected, then search for the "Lung Point" to determine the degree of PTX (see below).

Pleural and Pericardial Effusion, Echo Views - Pericardial Site (PCS) views. The bilaterally-applied PeriCardial Site (PCS) views on both the left and right sides are used to screen for the presence of pleural and pericardial effusion; and the right side for TFAST® echocardiography views including for volume status and contractility assessment via the left ventricular short-axis "mushroom" view (LVSA), for the "quick peek" short-axis left atrial to aortic ratio (LA:Ao) to screen for left-sided cardiac problems (increased left atrial filling pressure); and for the long-axis 4-chamber view to screen for right-sided conditions (RV:LV) (increased right ventricular filling pressures); and the long-axis 4-chamber view with the left ventricular outflow tract (LVOT) for abnormalities within the LVOT and aorta. The use of the PA:Ao (PA, pulmonary artery, Ao, aorta) ratio may also be learned as an add-on skill because the PA:Ao is accessible at the short-axis LA:Ao view and the long-axis 4-chamber view.

The TFAST® Echo Views and The Global FAST® Fallback View Strategies

"Global FAST® Non-echo Fallback Views" are hugely impactful for 2 major reasons. **First,** when performing the TFAST® echo views, suspect problems may be double-checked with its fallback views. For example, the sonographer thinks that the LA:Ao is increased, then uses Vet BLUE® and finds that the lung is dry (absent B-lines),and therefore no evidence of any clinically-relevant left-sided congestive heart failure. The patient may have left-sided heart disease, but has no evidence of left-sided *congestive* heart failure, important clinical information. Conversely, if Vet BLUE® shows wet lung, and its regional, pattern-based approach supports left-sided *congestive* heart failure (versus pneumonia), then there is an urgency to continue the work-up and treat the patient. The same logic holds for an increased RV:LV, however, the caudal vena cava and its associated hepatic veins are used for assessment, because right-sided congestive heart failure results in hepatic venous congestion and thus at the DH view, a distend caudal vena cava and its associated hepatic veins (Tree Trunk Sign). As for poor volume, the caudal vena cava is also assessed. A flat (small maximum height) cava supports more severe depletion than a caudal vena cava with a bounce. And, Vet BLUE® and the DH View should always be used in tandem to assess for left-and right-sided congestive heart failure to better assess and treat and monitor the patient. As for poor contractility, Vet BLUE® and the DH view are used to screen for concurrent left- and right-sided failure. **Second,** the "Global FAST® Non-echo Fallback Views" are used when it's too risky for TFAST® echo views because of patient status, or because the patient is difficult to image. Dry lung, or absent B-lines on Vet BLUE®, rules out left-sided *congestive* heart failure; and a "bounce" to the caudal vena cava along with an absence of

hepatic venous distension (no Tree Trunk Sign), rules out right-sided *congestive* heart failure. Typically, these "Global FAST® Non-echo Fallback Views" are easier to acquire in critical patients than the TFAST® echo views; and TFAST® echo views or complete echocardiography can wait until the patient is more stable. *See Global FAST® Proceedings for greater detail.*

The TFAST® Diagnosis of Pericardial versus Pleural Effusion

When performing the TFAST® left and right PeriCardial Site (PCS) Views make it a habit to have enough depth to see the heart globally or in other words in its entirety. Your landmark is the hyperechoic (bright white) pericardium in the far-field. The sonographer should be aware that too shallow of depth easily leads to the possibility of mistaking heart chambers for pleural and/or pericardial effusion especially in distressed patients that provide only quick glimpses of the heart (short-lived acoustic windows) due to air interference from lung. The concept is illustrated in the images below.

New: The TFAST® Slide for Pleural Effusion. The probe is slid caudal first and then cranial to the heart into the gravity dependent regions called the "cardiac diaphragmatic pouch" and the "cardiac cervical pouch" with "pouch" inferring the most gravity dependent region away from the heart where fluid would pocket. The detection of pleural effusion is confirmed by the observation of the "curtain sign" of pleural effusion.

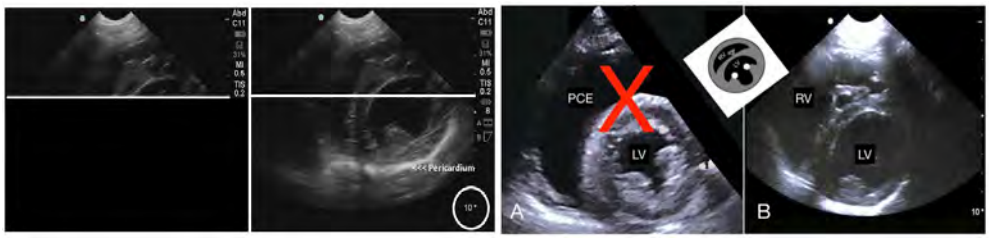

Figure on the Left. Make Sure You Image the Heart in Its Entirety. Shows how having *too shallow depth* can lead to serious mistakes. To the left, the image shows how it is difficult to accurately distinguish pleural or pericardial effusion from the crescent-shaped right ventricle, that, in haste, can be easily mistaken for pleural or pericardial effusion and its papillary muscles for pathology (see the next figure). Insist as best practice to always image the heart *in its entirety* using the hyperechoic (bright white) line of the pericardium in the far-field as your habitual landmark. *This material is reproduced with permission of John Wiley & Sons, Inc., Point-of-Care Ultrasound Techniques for the Small Animal Practitioner, 2nd Edition, Wiley ©2020 and Greg Lisciandro, Hill Country Veterinary Specialists, FASTVet.com ©2014, 2020.*

Figure on the Right. The Right Ventricle Mimicks Pericardial Effusion - The Danger of this View. The figure shows how the short-axis "mushroom" and its other short-axis views are dangerous as a single view for the non-cardiologist sonographer for the following reason: the image to the left shows pericardial effusion labeled as "PCE" compared to the image to the right that shows how the normal cardiac anatomy of the crescent-shaped right ventricle (RV) can mimic pericaridal (or pleural effusion). This mistake, common enough, leads to the most potentially catastrophic of interventions of performing centesis on a heart chamber (Lisciandro JVECC 2016). Best practice is *not* use the right Pericardial (parasternal) left ventricular short-axis views for pleural and pericardial effusion *unless combined with* other views because the mistake is easy to make without this TFAST® mindset. *This material is reproduced with permission of John Wiley & Sons, Inc., Point-of-Care Ultrasound Techniques for the Small Animal Practitioner, 2nd Edition, Wiley ©2020 and Greg Lisciandro, Hill Country Veterinary Specialists, FASTVet.com ©2014, 2020.*

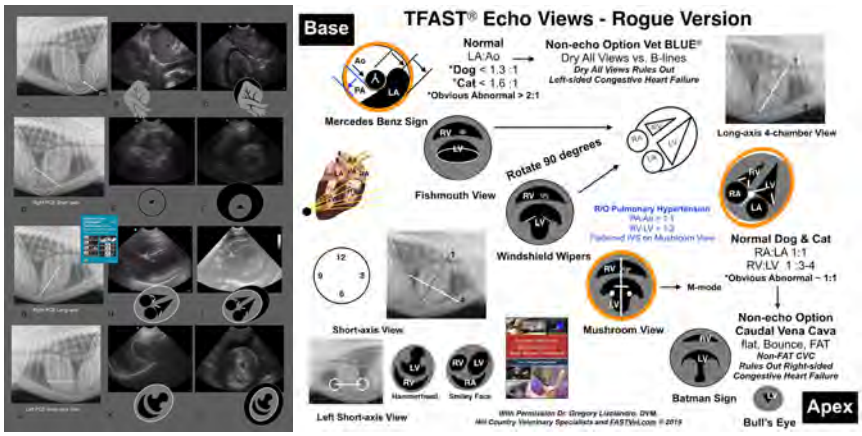

Figure. Pericardial Effusion Composite and TFAST® Echo Chart. In the first column are didactic radiographic images showing the scanning planes for each respective row of images of which there is normalcy to the right of each radiograph followed by pericardial effusion for that respective view. Note that the "Hammerhead View" from the left TFAST® PCS view is also an acceptable view (see TFAST® Echo Chart), because there are only 2 heart chambers located there, the left and right ventricles, and both ventricles may be clearly identified with fluid outside of them. Thus, it is difficult on both the long-axis 4-chamber view (G,H,I) and "Hammerhead View" (J,K,L) to mistake a heart chamber for pericardial (or pleural) effusion. *This material is reproduced with permission of John Wiley & Sons, Inc., Point-of-Care Ultrasound Techniques for the Small Animal Practitioner, 2nd Edition, Wiley ©2020 and Greg Lisciandro, Hill Country Veterinary Specialists, FASTVet.com ©2014, 2020.*

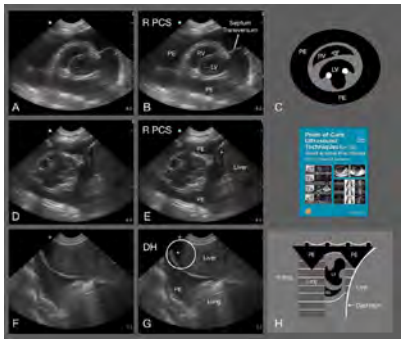

Figure. Pleural Effusion Composite. Shown are examples for pleural effusion from the TFAST® PCS views and the TFAST®-AFAST® DH view. Note how triangulations similar to ascites exist for pleural effusion, unlike pericardial effusion, that is rounded being contained within the pericardial sac. Another manner in which to diagnose pleural effusion is by default, in other words, it is *not* pericardial effusion, which is much easier to identify, and thus is pleural effusion. *This material is reproduced with permission of John Wiley & Sons, Inc., Point-of-Care Ultrasound Techniques for the Small Animal Practitioner, 2nd Edition, Wiley ©2020 and Greg Lisciandro, Hill Country Veterinary Specialists, FASTVet.com ©2014, 2020.*

TFAST® Diagnosis of Pericardial Effusion The Gold Standard for the Diagnosis of Pericardial Effusion is Ultrasound - Radiography is Unreliable Pericardial Effusion is Contained in the Pericardial Sac that Attaches at One Atrium and Rounds the Muscular Apex of the Heart to Attach to the Other Atrium		
Imaging Strategy	**TFAST® DH View**	**TFAST® PCS View**

*Image toward the muscular apex of the heart where no heart chambers can be mistaken for free fluid	*TFAST® DH View – Racetrack Sign	*TFAST® Right PCS View – Bull's Eye Sign
*Long-axis 4-chamber view where all 4 chambers are identified		*TFAST® Right PCS View
*Image the heart globally in its entirety using the bright white pericardium in the far-field as a landmark	Make Habitual Best Practice for Echo Views	Make Habitual Best Practice for Echo Views
TFAST® Diagnosis of Pleural Effusion The Gold Standard for the Diagnosis of Pleural Effusion is Debatably Computerized Tomography Radiography is Generally Good Pleural Effusion is Uncontained and Unrestrained Unless Compartmentalized		
Imaging Strategy	**TFAST® DH View**	**TFAST® PCS View**
*Image the heart globally in its entirety using the bright white pericardium in the far-field as a landmark		*TFAST® Right and Left PCS – Anechoic (Black) Triangulations
*Image toward the muscular apex of the heart where no heart chambers can be mistaken for free fluid	*TFAST DH View – Anechoic (Black) Triangulations	
*"TFAST® Slide" caudally and then cranially into the "cardiac-diaphragmatic pouch" and the "cardiac-cervical pouch"		"Curtain Sign" for pleural effusion
Gregory Lisciandro, DVM, DABVP, DACVECC, FASTVet.com and Hill Country Veterinary Specialists *© 2016, 2018, 2019*		

Clinical Indications/Applications for TFAST® - Global FAST® is Our New Quick Assessment Test

The use of *standardized* TFAST® and Vet BLUE® should serve as routine as an "extension of the physical exam" for all dogs and cats that are abnormal or respiratory suspects (*better* the Global FAST® Approach). Questionable findings within the thorax using the FAST DH View should be confirmed via TFAST® PCS View(s) or Vet BLUE® or both and by serial exams, repeating TFAST® and Vet BLUE® at least once 4-hours later.

Goal-Directed Templates for TFAST®

*****Right and left sides are listed in templates for the CTS and PCS views

***Chest Tube Site (CTS) - Glide Sign?** **Present** (normal) -- no Pneumothorax **or** **Absent** – Pneumothorax **or Indeterminate** or **Not Assessed**

***Location of Lung Point?** **Upper 1/3** or **Middle 1/3** or **Lower 1/3** or **Indeterminate** or **Not Assessed**

***CTS - Lung Rockets (also called B-lines)**? **Present** (no PTX) – interstitial lung fluid (edema, hemorrhage) or **Absent** – no interstitial lung fluid or **Indeterminate** or **Not Assessed**

***CTS - Step Sign?** **Present** – concurrent thoracic wall trauma (rib fractures, hematoma, intercostal muscle tear) or pleural space disease is suspected or **Absent** - no concurrent thoracic wall trauma or pleural space disease is suspected or **Indeterminate** or **Not Assessed**

***PCS view - Pleural or Pericardial Eff.?** **Absent**- no pleural or pericardial fluid

or **Present** - pleural or pericardial fluid **or** both (mild, moderate, or severe) or **Indeterminate** or **Not Assessed**

TFAST Echo® Views:

Left Ventricular Short-axis Mushroom View (LVSA): Filling: **Adequate** suggesting normovolemia or **Inadequate** suggesting hypovolemia or **Indeterminate** or **Not Assessed**
Contractility: **Unremarkable** or **Decreased** or **Indeterminate** or **Not Assessed**

Left Atrial to Aortic Ratio (LA:Ao) on Short-axis:
Unremarkable or **Increased** or **Indeterminate** or **Not Assessed**

Right Ventricular to Left Ventricular Ratio (RV:LV) on Long-axis:
Unremarkable or **Increased** or **Indeterminate** or **Not Assessed**

DH View:
Pleural effusion: **Absent** or **Present (mild, moderate, severe)** or **Indeterminate** or **Not Assessed**
Pericardial effusion: **Absent** or **Present (mild, moderate, severe)** or **Indeterminate** or **Not Assessed**
$**Hepatic Venous Distension:** **Present** or **Absent** or **Indeterminate** or **Not Assessed**
&**Caudal Vena Cava Characterization:** **FAT** or **flat** or **bounce** or **Indeterminate** or **Not Assessed**

Cardiac Tamponade: **Present or Absent or Indeterminate** or **Not Assessed**

Comments: _____

KEY: CTS = chest tube site; **PCS** = pericardial sac; **LV** = left ventricle, **PTX** = pneumothorax, **NA** = Not Assessed.

Note: The TFAST® is a rapid ultrasound procedure used to help detect major chest wall, lung, and pleural and pericardial space problems as a screening test in order to better direct resuscitation efforts, help better direct diagnostics, and manage hospitalized critically ill patients. TFAST® exam is not intended to replace thoracic radiographs, or complete echocardiography.

$The hepatic veins should *not* be apparent in both dogs and cats placed in lateral recumbency or standing or sternal. When imaged, the branching has been referred to as the "Tree Trunk Sign."

&The caudal vena cava can be alternatively referred to as a bounce = fluid responsive cava (~35-50% diameter change); FAT = fluid intolerant cava (distended with increased maximum height < 1cm in dogs < 9kg, and > 1.5cm in dogs > 9kg with little maximum height change [< 10%]); flat = hypovolemic cava (small with decreased maximum height of < 0.3cm in dogs < 9kg and < 0.5cm in dogs > 9kg with little maximum height change [< 10%]). *See Global FAST® Monitoring Proceedings.*

Template provided by Dr. Gregory Lisciandro, DVM, DABVP, DACVECC, FASTVet.com and Hill Country Veterinary Specialists Copyright 2018, 2019, 2020 for your use and modification.

References & Further Reading

1. **Lisciandro GR,** Lagutchik MS, Mann KA, et al. Evaluation of a thoracic focused assessment with sonography for trauma (TFAST) protocol to detect pneumothorax and concurrent thoracic injury in 145 traumatized dogs. *J Vet Emerg Crit Care* 2008; 18(3): 258-269.
2. **Lisciandro GR**. Focused abdominal (AFAST) and thoracic (TFAST) focused assessment with sonography for trauma, triage and monitoring in small animals. *J Vet Emerg Crit Care* 2011; 20(2):104-122.

3. **Lisciandro GR**, Fosgate GT, Fulton RM. Frequency of ultrasound lung rockets using a regionally-based lung ultrasound examination named veterinary bedside lung ultrasound exam (Vet BLUE) in 98 dogs with normal thoracic radiographical lung findings. *Vet Rad Ultrasound* 2014; 55(3):315-22.
4. **Lisciandro GR.** Evaluation of initial and serial combination focused assessment with sonography for trauma (CFAST) examination of the thorax (TFAST) and abdomen (AFAST) with the application of an abdominal fluid scoring system in 49 traumatized cats. Abstract. *J Vet Emerg Crit Care* 2012; 22(2):S11.
5. Hall DJ, Shofer F, Meier CK, Sleeper MM. Pericardial effusion in cats: a retrospective study of clinical findings and outcome in 146 cats. *J Vet Intern Med* 2007;21(5): 1002-7.
6. MacDonald KA, Cagney O, Magne ML. Echocardiographic and Clinicopathologic Characterization of Pericardial Effusion in Dogs: 107 Cases (1985-2006). J Am Vet Med Assoc 2009; 235(12):1456-1461.
7. Stafford Johnson M, Martin M, Binns S, et al. A Retrospective Study of Clinical Findings, Treatment and Outcome in 143 Dogs With Pericardial Effusion. J Sm Anim Pract 2004; 45(11): 546-552.
8. Ward JL, **Lisciandro GR**, DeFrancesco TD, et al. Evaluation of Point-of-care Thoracic Ultrasound and NT-proBNP for the Diagnosis of Congestive Heart Failure in Cats with Respiratory Distress. *J Vet Intern Med* 2018; 32(5): 1530-1540.
9. **Lisciandro GR.** The use of the diaphragmatico-hepatic (DH) view of the abdominal and thoracic focused ultrasound techniques with sonography for triage (AFAST/TFAST) examinations for the detection of pericardial effusion in 24 dogs (2011-2012). *J Vet Emerg Crit Care* 2016; 26(1): 125-31.
10. McMurray J, Boysen S, Chalhoub S. Focused assessment with sonography in nontraumatized dogs and cats in the emergency and critical care setting. *J Vet Emerg Crit Care* 2016; 26(1): 64-73.
11. **Lisciandro GR.** The cardiac gallbladder: Case series of 13 dogs and 1 cat with sonographically-detected gallbladder wall edema. Abstract. *J Vet Emerg Crit Care 2019; 29(S1): S24.*
12. **Lisciandro GR**. Chapter 3: Point-of-care Ultrasound. *In:* Small Animal Diagnostic Ultrasound, edited by Mattoon JS, Sellon R, and Berry CR. Elsevier: St. Louis, MO, *In Press* 2019.
13. **Lisciandro GR**. Editor, Point-of-care Ultrasound Techniques for the Small Animal Practitioner, 2nd Edition, Wiley-Blackwell: St. Louis, ©2020.

See also Vet BLUE® Proceedings for additional References.

Vet BLUE® Introduction to Its Regional, Pattern-based Approach,
Its B-line Scoring System, and Its Visual Lung Language for the Respiratory Patient

Emerald Coast Veterinary Conference, Sandestin, FL, USA
Gregory R. Lisciandro, DVM, Dipl. ABVP, Dipl. ACVECC
Hill Country Veterinary Specialists & FASTVet.com, Spicewood, Texas USA
Email LearnGlobalFAST@gmail.com
Cell 210.260.5576
Website FASTVet.com

Textbook Point-of-care Ultrasound Techniques for the Small Animal Practitioner, 2nd Edition, Wiley ©2021

Use of Lung Ultrasound in Small Animals - The Vet BLUE®

The historical reluctance to proactively apply lung ultrasound (LUS) to small animals with respiratory distress is irrational in many respects. The overriding belief that air-filled lung creates insurmountable obstacles, and the continued belief in small animal medicine that imaging lung is difficult to perform leading to mistakes, perpetuate its delayed use in small animal veterinary medicine.

TFAST® (2008), referring to our thoracic FAST protocol, was the first standardized abbreviated veterinary ultrasound exam of the thorax. TFAST® included the Chest Tube Site (CTS) for the detection of pneumothorax (PTX) and lung contusions; the Pericardial Sites for the detection of pleural and pericardial effusion plus fundamental echocardiography views; and the Diaphragmatico-Hepatic View for pleural and pericardial effusion, cardiac imaging, and lung imaging along the pulmonary-diaphragmatic interface. Moreover, the TFAST® DH View may also be used for assessing volume status via characterization of the caudal vena cava and hepatic veins.

With the finding of lung pathology during TFAST®, the author extended the lung examination from the TFAST® CTS View with an additional 6 regional lung views plus the Diaphragmatico-Hepatic View. This novel regional pattern-based proactive LUS exam was named Vet BLUE® - "Vet" for "veterinary" and "BLUE" for "brief lung ultrasound exam" and "BLUE" also implying cyanosis and all respiratory small animals. The Vet BLUE® protocol was developed in 2010, being the first published proactive LUS protocol. Vet BLUE®is also the most studied in our veterinary literature with over 8 peer-reviewed publications.

The Fundamentals of Vet BLUE®

Patient Preparation. Vet BLUE® sites are not shaved! All images shown by the author are from unshaved sites. To optimize the image quality, the fur is wetted with minimal amounts of 70% isopropyl alcohol, the fur parted to expose the skin, followed by the application of gel and the probe head then directly opposed to skin. A common mistake is placing the probe head on a wetted mat of hair, which leads to the phenomenon of air trapping within the wetted mat. Air trapping causes the deflection of the echoes from the probe because ultrasound cannot transit through air; and minimizing the numbers of echoes making it to the region of interest compromises image quality.

Patient Positioning. Vet BLUE® is preferably performed in standing (or sternal) which is safer for dogs and cats respiratory compromised, in respiratory distress, or those that are hemodynamically fragile or unstable. A roll of towels (or paper towels) under the forelegs of a cat is an easy tolerated maneuver to gain access to the ventral Vet BLUE® views, and the TFAST PeriCardial Site views. Vet BLUE® may also be performed in dogs and cats in lateral recumbency when they are laterally recumbent. The concept that air rises to least gravity-dependent regions and fluid conversely falls to most gravity-dependent regions should be kept in mind relative to patient positioning. This concept is especially important when drawing conclusions regarding pneumothorax (PTX)

because free air in the pleural cavity (rises); and pleural effusion because free fluid in the pleural cavity (falls) into gravity dependent areas. Pericardial effusion also falls into gravity dependent regions but is contained within the pericardial sac.

Probe Type. The curvilinear (convex) probe is the preferred probe in human medicine by the non-radiologist. In veterinary medicine, the curvilinear (microconvex) probe is also most preferred because it is flexible enough to be used to image all aspects of the Global FAST® Approach, which includes AFAST®, TFAST®, and Vet BLUE®, our lung ultrasound protocol. The linear probe may also be used, and it does in fact give exceptional detail of the lung surface, however, it is unnecessary. The linear probe has the disadvantage of not being able to extend beyond Vet BLUE® to AFAST® and TFAST®. The phased-array cardiac probe should not be used because it cannot accurately identify the gator sign orientation or count numbers of B-lines.

Probe Frequency. Generally, frequencies of 5-10MHz adequately image lung. Other considerations that affect the image include the focus position, which should be across or just below the "lung line", the time gain compensation and overall gain, generally turned down for more contrast, however, with enough gain to image through the far field, and the preset. The author uses the abdominal preset for the entire Global FAST® Approach, including lung and heart. This saves time and works well once the sonographer becomes experienced with their machine. Other factors discussed below include proper orientation, depth, and manipulating the echoes to your advantage. The one-eyed gator sign (rib in the center of the screen) and manipulating the angle of insonation, when imaging the "lung line", optimize the image.

Lung Imaging Orientation. All LUS orientation is founded on the visualization of the "gator sign" for its importance in properly identifying the intercostal space. By identifying the intercostal space, the "lung line" may be identified, which has also been referred to as the pulmonary-pleural interface, where visceral and parietal pleura are directly opposed.

We prefer to use "lung line" because when pathology exists within the pleural space, the lung is displaced away from the parietal pleura. The scanning plane is oriented perpendicular to the long axis of the ribs with the probe marker and screen orientation marker toward the head and to the left of the screen, respectively.

By doing so, the head will be to the left of the screen (cranial) and the tail to the right of the screen (caudal). Depth is generally set between 4-8 cm with a good way to remember is the l-u-n-g has 4 letters, so start with 4cm for small dogs and cats and increase to 8cm (sometimes greater) for large dogs. If the "gator sign" is not identified then other bright white or hyperechoic lines can easily be mistaken for the "lung line" including the spine of the scapula, an air-filled stomach, A-lines, and even fascial planes within thorax-associated muscle.

The "GATOR SIGN" – Fundamental Lung Ultrasound Orientation

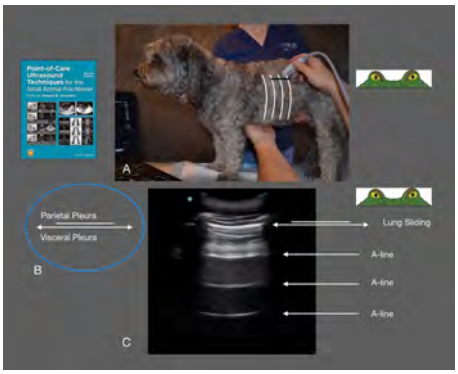

Figure. Gator Sign Orientation. The rounded ribs are likened to the eyes, and the bright white hyperechoic "lung line" or "pulmonary-pleural interface" to the bridge of its nose as a partially submerged alligator (gator) peers at the sonographer. The proximal bright white, hyperechoic line, is the focus of ALL lung ultrasound to ensure one accurately

identifies where lung is expected to be in normalcy, referred to as the "Lung Line." The "Lung Sliding" may be described as sliding pleural and visceral pleura (micro level) versus the author's preference of lung sliding along the thoracic wall (macro level). *This material is reproduced with permission of John Wiley & Sons, Inc., Point-of-Care Ultrasound Techniques for the Small Animal Practitioner, 2nd Edition, Wiley ©2020 and FASTVet.com © 2014, 2020 and the "Gator Sign" in the veterinary literature (Lisciandro et al. Vet Radiol Ultrasound 2014).*

The Vet BLUE® - Its 9 Acoustic Windows

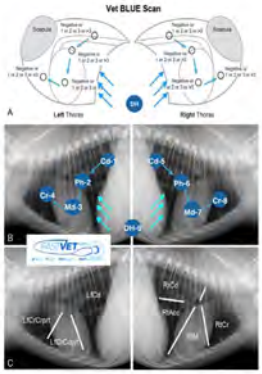

This material is reproduced and modified with permission of John Wiley & Sons, Inc., Focused Ultrasound Techniques for the Small Animal Practitioner, Wiley ©2014 and FASTVet.com © 2014

How to Perform. There is no shaving of hair. Small amounts of 70% isopropyl alcohol are used to wet and part the hair for direct visualization of the skin, followed by alcohol-based hand sanitizer or commercially available acoustic coupling gel. The Vet BLUE® begins at the CTS view of TFAST® and establishing the "gator sign" orientation. The probe is then moved through regional locations that are bilaterally applied as follows: caudodorsal lung region, perihilar lung region, middle lung region, and lastly the cranial lung region. The methodology has changed from our original protocol by better defining each regional view by locating the caudodorsal transition zone (CdTZ). The CdTZ is located by starting directly above the xiphoid in the upper third of the thorax and locating the "curtain sign" effect that distinguishes between pleural and abdominal cavities. If it is not immediately located, the probe is generally slid caudally searching for obvious abdominal structures and then sliding cranially finding the "curtain sign." The principle is very important because abdominal structures are easily mistaken for lung pathology without this training.

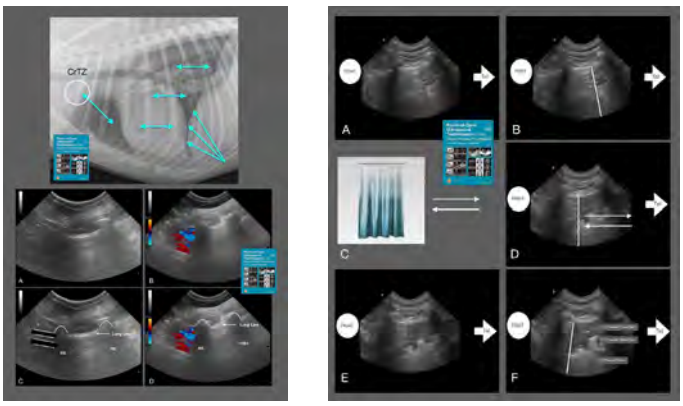

Figure. Caudal and Cranial Vet BLUE® Transition Zones. The composite to the left is the cranial transition zone found by sliding along the "Lung Line" unit it ends in the soft tissue of the thoracic inlet with its jugular and carotid vessels. The caudal transition zone is identified by the "Curtain Sign" and the linear border of air that identifies the pleural cavity to the left and the abdominal cavity to the right. *This material is reproduced with permission of John Wiley & Sons, Inc., Point-of-Care Ultrasound Techniques for the Small Animal Practitioner, 2nd Edition, Wiley ©2020 and FASTVet.com © 2014, 2020.*

Once the CdTZ is located, the probe is slid 2-3 intercostal spaces cranially and away from the CdTZ. While sliding away from the CdTZ lung can be evaluated for pathology since the sonographer knows they are in fact over the pleural cavity. The location 3 intercostal spaces away from the CdTZ is considered the starting point. Its intercostal space is surveyed and then the sonographers slides one space caudally over its intercostal space, returns to the primary ICS and then moves one more ICS cranially so that a minimum of 3 ICSs are interrogated at the caudodorsal lung region. A line, referred to as the "Vet BLUE Line", is then drawn from the caudodorsal starting point to the patient's elbow and approximately halfway to the elbow is the perihilar region. The methodology is repeated as done previously. Interrogating the primary ICS, sliding caudally and interrogating its ICS, before returning to the primary and sliding one ICS cranially, again imaging a minimum of 3 ICSs. The middle lung region is generally at the level of the elbow in a standing dog or cat. The heart is a good landmark and when found ventrally, the probe is moved dorsally until the "gator sign" is located immediately dorsal to the heart. The methodology performed at the two previous views is repeated sliding caudally first, then back to the primary and another ICS cranially for a minimum of 3 ICSs. The cranial lung region is imaged a little differently by finding the cranial cervical transition zone (CrTZ) by following the "lung line" until it drops off into soft tissue of the thoracic inlet. The path for the Vet BLUE® is like a check mark, meaning as the sonographer slides cranially into the thoracic inlet, they must also slide dorsally. Assurance of being in the thoracic inlet is the presence of pulsating arteries with a rib shadow immediately caudal followed by the "gator sign" and a "lung line." The 3 ICSs at the cranial lung region are performed by sliding from the thoracic inlet and then the first rib, and counting first rib, first ICS, second rib, second ICS, third rib, third space. This completes the Vet BLUE® and we have found this protocol to be very repeatable compared to our original methodology. Another key (Vet BLUE® rule) is always slide caudally first anytime when imaging the thorax to always ask the question, where is the abdominal cavity? Another Vet BLUE® rule is that if you do not have a "gator sign" orientation you cannot confidently assess lung.

Always perform Vet BLUE® in this same order as findings are better remembered, starting left and finishing on the right if the patient allows. We believe the most efficient Global FAST® protocol in a standing patient is beginning with the left Vet BLUE® and then moving to the left TFAST® Pericardial Site followed by a standing AFAST® and Focused Spleen before moving to the right Vet BLUE®, right Pericardial Site and its TFAST® echocardiography views, and ending on the AFAST® Hepato-Renal 5th Bonus View. A video may be found in the Free Resources of the FASTVet.com website.

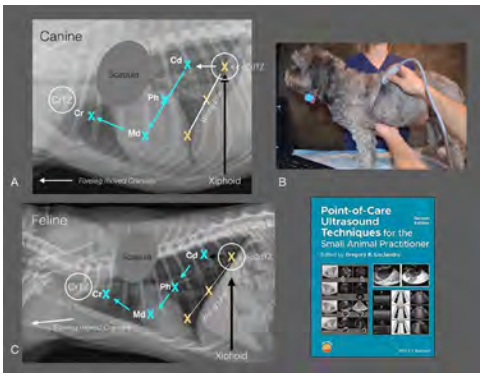

Figure. Selecting the Vet BLUE® Line. Find the Caudodorsal Transition Zone (CdTZ) by finding the "Curtain Sign" – see text for greater detail. The probe is slid 3 intercostal spaces cranial to the CdTZ for your starting Vet BLUE® view, the caudodorsal lung region view. From there survey 3 intercostal spaces, one caudal and one cranial from your starting point. Drawing a line to the elbow is performed next, this is your Vet BLUE Line. Approximately halfway is the perihilar lung region, and at the approximately of the elbow is the middle lung region. Then, the probe is slid cranio-dorsal into the thoracic inlet to find the Cranial Transition Zone (CrTZ). From the CrTZ the probe is lid caudally over the first rib, first

intercostal space, the second rib, second intercostal space, third rib, third intercostal space. This Vet BLUE® methodology is newer and more reproducible than previously published (Lisciandro et al. ongoing research 2020). *This material is reproduced with permission of John Wiley & Sons, Inc., Point-of-Care Ultrasound Techniques for the Small Animal Practitioner, 2nd Edition, Wiley ©2020 and Greg Lisciandro, Hill Country Veterinary Specialists, FASTVet.com © 2014, 2020.*

Vet BLUE® - Wet versus Dry Lung Concept

Dry Lung. Dry aerated lung at its surface is defined as a bright white, hyperechoic "lung line" accompanied with "lung sliding" and A-lines repeating through the far field. Remember A-lines as air reverberation artifact because "Air" begins with the letter "A." "Lung sliding" is the to and fro motion of the lung sliding along the intercostal space much like an Etch-a-Sketch cursor moving to and fro. The micro description for "lung sliding" is the sliding or parietal and visceral pleura. On a macro level, "lung sliding" the lung surface sliding along the intercostal space. The distinguishing feature between normal aerated lung on its surface and pneumothorax is presence and absence of "lung sliding", respectively. Each of these conditions is highlighted by a strong air interface at the intercostal space. From our Vet BLUE® research, expect absent B-lines at all views in adult dogs and cats and puppies and kittens over 6-weeks of age. A single B-line at a single regional view is uncommon but can be also support a "dry Vet BLUE® profile." The bottom line is to place any and all B-lines during Vet BLUE® in clinical context and record your findings for future comparison.

Wet Lung. Alveolar-interstitial edema creates a unique artifact referred to as B-lines or ultrasound lung rockets. These terms may be used interchangeably meaning the same thing. The use of "B" in B-lines is only because "B" follows "A" in the alphabet. The vertical laser-like bright white, hyperechoic streaks originate off the "lung line" while extending through the far field *without* fading while swinging like a pendulum in synchrony with phases of respiration. Their presence is referred to as alveolar-interstitial syndrome because a pattern-based approach is needed for developing a working diagnosis as to their cause. For the vast majority of our small animal patients, these unique artifacts in lung are created by the strong difference in acoustic impedance between fluid and air and the cuffing of air (alveoli) around fluid (Soldati personal communication). However, pleural surface fibrosis also can create the artifact and so may pulmonary nodules and ingesta within the stomach that can mimic lung as well, referred to as pseudo B-lines because these conditions do not represent forms of alveolar-interstitial edema.

Quick Facts - B-lines or ultrasound lung rockets do the following:

- Immediately rule out pneumothorax at that location on the thoracic wall
- Are lung contusion in trauma until proven otherwise
- Guide diuretic use in left-sided congestive heart failure patients
- Their absence with dry lung all Vet BLUE views rules out all common wet lung conditions including left-sided congestive heart failure, non-cardiogenic pulmonary edema, pneumonia, pulmonary hemorrhage, and lung contusions.

Vet BLUE® - Wet versus Dry Lung Approach in Respiratory Patients

From our Vet BLUE® research, expect absent B-lines at all views in adult dogs and cats and puppies and kittens over 6-weeks of age. A single B-line at a single regional view is uncommon but can be also support a "dry Vet BLUE® profile." The bottom line is to place any and all B-lines during Vet BLUE® in clinical context and record your findings for future comparison.

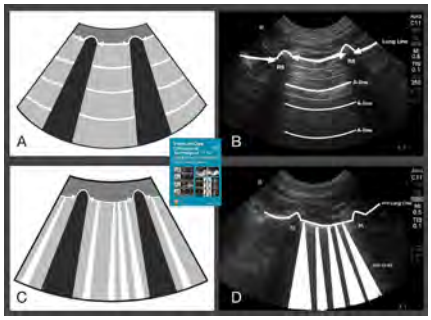

Figure. Wet versus Dry Lung. Dry Lung is defined as A-lines with "Lung Sliding." Wet Lung is defined as B-lines with hyperechoic laser like vertical streaks that obliterate A-lines and swing like a pendulum in respirophasic synchrony. If they don't follow this rule, then they are not B-lines (also called Lung Rockets). *This material is reproduced with permission of John Wiley & Sons, Inc., Point-of-Care Ultrasound Techniques for the Small Animal Practitioner, 2nd Edition, Wiley ©2020 and Greg Lisciandro, Hill Country Veterinary Specialists, FASTVet.com © 2014, 2020.*

It is important to work through the following cases and what would be expected in each barring complications: left-sided congestive heart failure in dogs other than Doberman Pinschers, left-sided congestive heart failure in cats; non-cardiogenic pulmonary edema (electrocution, strangulation, neurogenic); tracheal collapse, laryngeal paralysis, infectious tracheobronchitis (now referred to as CIRD, canine infectious respiratory disease), aspiration pneumonia, bacterial bronchopneumonia, pericardial effusion, pyrexia/fever/heat stroke, feline asthma, canine bronchial disease, canine anaphylaxis, feline anaphylaxis as common respiratory examples.

The most rapid and sensitive manner in which to rule out left-sided *congestive* heart failure is the use of Vet BLUE® and the finding of absent B-line, dry lung all Vet BLUE® views (plus all other common wet ling conditions).

Rule Outs for Dry Lung All Vet BLUE® Views
RESPIRATORY
Pulmonary Thromboembolism (PTE)
Pneumothorax
Dynamic Upper Airway Conditions (e.g., Collapsing Trachea, Laryngeal Paralysis)
Upper Airway Obstruction (e.g., Mass, Oropharyngeal Swelling)
Chronic Obstructive Pulmonary Disease (COPD), Bronchitis
Feline Asthma
Tracheobronchitis (e.g., Infectious, Inflammatory, Irritant)
Centrally located lung pathology away from the lung line (missed by Vet BLUE)
CARDIAC
Pericardial Effusion / Cardiac Tamponade
Cardiac Arrhythmia
Dilated Cardiomyopathy (DCM)
Right-sided Congestive Heart Failure (CHF)
*Pulmonary Hypertension
UNDIFFERENTIATED HYPOTENSION
Canine Anaphylaxis
Hemoabdomen
Hemothorax
Hemoretroperitoneum
Cavitary Effusion
Gastric Dilatation Volvulus/Bloat
Sepsis
OTHER NON-RESPIRATORY

Pyrexia / Heat Stroke
High Fever
Severe Metabolic Acidosis
Severe Anemia
Note: Dry Lung All Vet BLUE® Views Rules Out Clinically-Relevant Wet Lung Conditions
***Pulmonary Hypertension can be Wet Lung as well*
Gregory Lisciandro, DVM, FASTVet.com, Copyright 2015

Pseudo B-lines

Ingesta in the stomach and nodules also cause B-lines similar to the differences in acoustic impedance and cuffing of alveoli around fluid with forms of alveolar-interstitial edema. We call these "pseudo B-lines" to differentiate them from alveolar interstitial edema and categorize them as a different subset.

Vet BLUE® Scoring System

In 2006, Volpicelli and colleagues showed that numbers of B-lines on LUS correlated with degree of alveolar-interstitial edema on computed tomography (CT) in human lung. This is truly a remarkable finding because LUS may be performed point-of-care, is rapid and radiation sparing, and time sensitive whereas CT is expensive, limited availability, risky and is comparable to 100 chest x-rays. We developed a Vet BLUE® B-line Scoring System taking the maximum number of B-lines over a single intercostal space at each respective Vet BLUE® region as 1, 2, 3, >3, and infinity.

Vet BLUE® Scoring System Use for Guiding Diuretic Usage

By using the Vet BLUE® B-line Scoring System in cases with known left-sided *congestive* heart failure, our scoring carries the potential to guide loop diuretic therapy by using the strong positive model of >3 and infinity being strong positive and 1, 2, and 3 as being weak positive. Loop diuretic therapy in the author's opinion is as abused as any other drug like glucocorticoids by its administration empirically in respiratory patients without evidence-based information; and lack of sensitive ways to determine the degree of alveolar-interstitial edema based on lung auscultation and thoracic radiography. Now, Vet BLUE® is your new more sensitive tool for guiding loop diuretic therapy and preventing its many side effects of metabolic alkalosis, hemoconcentration and renal injury and failure.

Vet BLUE® Scoring System Use for Lung Contusion Severity

The use of maximum numbers of B-lines over numbers of positive regional Vet BLUE® views provides a lung contusion scoring system. By recording results, lung contusions may be monitored for worsening, their resolution or without change (static).



Figure. The Vet BLUE® B-line Scoring System. The Vet BLUE® B-line Scoring System for Use in Wet versus Dry Lung, Guiding Diuretic Use in Left-sided Congestive Herat Failure, and Assessing and Severity and Monitoring Lung Contusions (and Pulmonary Hemorrhage). *This material is reproduced with permission of John Wiley & Sons, Inc., Point-of-Care Ultrasound Techniques for the Small Animal Practitioner, 2nd Edition, Wiley ©2020 and Greg Lisciandro, Hill Country Veterinary Specialists, FASTVet.com © 2014, 2020.*

Vet BLUE® Visual Lung Language for Signs of Consolidation

The lecture will briefly touch on signs of consolidation of Shred Sign (air bronchogram), Tissue Sign (hepatization of lung), Nodule Sign, and Wedge Sign (pulmonary thromboembolism).

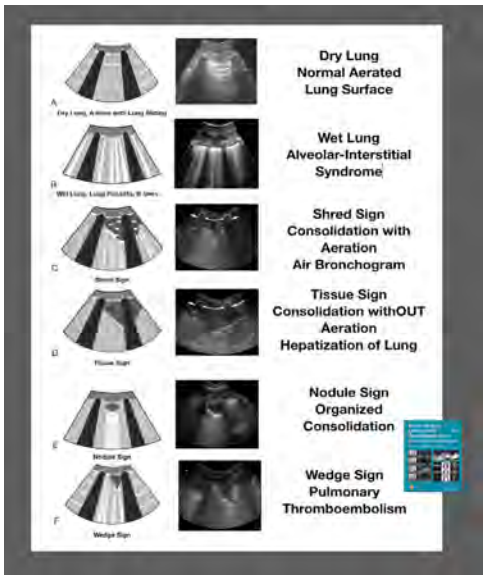

Figure. Vet BLUE® Visual Lung Language and Its 6 Signs. Vet BLUE® Visual Lung Language from most to least normal, from less severe to more severely affected lung as Dry Lung to Wet Lung (alveolar-interstitial edema) to Shred Sign (air bronchogram) to Tissue Sign (hepatization of lung) to Nodule Sign to Wedge Sign (pulmonary thromboembolism). *This material is reproduced and modified with permission of John Wiley & Sons, Inc., Point-of-Care Ultrasound Techniques for the Small Animal Practitioner, Wiley ©2014, ©2020 and Greg Lisciandro, Hill Country Veterinary Specialists and FASTVet.com © 2020.*

Comparison of Vet BLUE® to Thoracic Radiography and Computed Tomography

Vet BLUE® is proving itself as a more sensitive test than thoracic radiography for wet lung conditions (types of alveolar-interstitial edema) and pneumothorax comparing much more closely to computed tomography (CT). We have several clinical studies published, in press, and in the process of being submission for peer review that support this statement. As for types of consolidation including nodules, more studies are needed to make a statement on the performance of Vet BLUE® to thoracic radiography and CT. One recent study of which the author was involved showed that Vet BLUE® was similar but not superior to thoracic radiography in sensitivity and specificity for pulmonary nodules.

Always Strive for The GLOBAL FAST® APPROACH

"Selective imaging" leads to "confirmation bias error" and "satisfaction of search error" and is a major concern with the POCUS movement. For example, a Vet BLUE® profile on a large breed dog is dry all Vet BLUE® views and along with an unremarkable thoracic radiograph the conclusion is drawn that the dog has upper airway or bronchial disease. However, the Global FAST® Approach provides an unbiased set of 15 data imaging points of the abdomen and thorax including heart and lung surface. By using this standardized global approach important findings are integrated into the final assessment. In fact, this dog has obvious poor contractility on TFAST®

echocardiography views (likely dilated cardiomyopathy), and on AFAST® has a splenic mass with a negative AFAST® abdominal fluid score of 0. In this case you can see how integrating the Global FAST® Approach provided a much better patient assessment over thoracic radiography (and physical exam and blood and urine testing).

References & Further Reading

1. **Lisciandro GR**, Lagutchik MS, Mann KA, *et al*. Evaluation of a thoracic focused assessment with sonography for trauma (TFAST) protocol to detect pneumothorax and concurrent thoracic injury in 145 traumatized dogs. *J Vet Emerg Crit Care* 2008; 18(3):258.
2. **Lisciandro GR.** Abdominal (AFAST) and thoracic (TFAST) focused assessment with sonography for trauma, triage, and tracking (monitoring) in small animal emergency and critical care. *J Vet Emerg Crit Care 2011; 21(2): 104-119.*
3. **Lisciandro GR,** et al. Frequency and number of ultrasound lung rockets (B-lines) using a regionally based lung ultrasound examination named Vet BLUE (veterinary bedside lung ultrasound exam) in dogs with radiographically normal lung findings. V*et Radiol and Ultrasound 2014;55(3): 315-22.*
4. **Lisciandro GR**, et al. Frequency and number of ultrasound lung rockets (B-lines) using a regionally based lung ultrasound examination named Vet BLUE (veterinary bedside lung ultrasound exam) in cats with radiographically normal lung findings. *J Vet Emerg Crit Care 2017; 27(3):267-277.*
5. Ward JL, **Lisciandro GR**, Tou SP, Keene BW, DeFrancesco TC. Accuracy of point-of-care lung ultrasound (Vet BLUE protocol) for the diagnosis of cardiogenic pulmonary edema in dogs and cats with acute dyspnea. *J Am Vet Med Assoc 2017 250(6): 566-579.*
6. Ward JL, **Lisciandro GR**, DeFrancesco TD, et al. Evaluation of Point-of-care Thoracic Ultrasound and NT-proBNP for the Diagnosis of Congestive Heart Failure in Cats with Respiratory Distress. *J Vet Intern Med* 2018; 32(5):1530-1540.
7. Ward JL, **Lisciandro GR**, Ware WA, Miles KG, DeFrancesco TC. Lung ultrasound findings in 100 dogs with various etiologies of cough. *J Am Vet Med Assoc* 2019;255(5): 574-583.
8. **Lisciandro GR**, Ward JL, DeFrancesco TC, Mann KA. Absence of B-lines on Lung Ultrasound (Vet BLUE protocol) to Rule Out Left-sided Congestive Heart Failure in 368 Cats and Dogs. *Abstract, J Vet Emerg Crit Care 2016; 26(S1): S8.*
9. Ward JL, **Lisciandro GR**, DeFrancesco TC. Distribution of alveolar-interstitial syndrome in dyspneic veterinary patients assessed by lung ultrasound versus thoracic radiographs. *J Vet Emerg Crit Care,* 2018;28(5):415-428.
10. Dicker SA, **Lisciandro GR,** Newell SM, et al. Diagnosis of pulmonary contusions with point-of-care lung ultrasonography and thoracic radiography compared to thoracic computed tomography in dogs with motor vehicle trauma: 29 cases (2017-2018). *Accepted, In Press, J Vet Emerg Crit Care, May 2019.*
11. **Lisciandro GR**. Chapter 55: Ultrasound in Animals. In Critical Care Ultrasound (human textbook), Editors Lumb and Karakitsos. Elsevier: St. Louis, MO 2014.
12. **Lisciandro GR**. Chapter 10: The Vet BLUE Lung Scan. In Focused Ultrasound for the Small Animal Practitioner, Editor, Lisciandro GR. Wiley Blackwell: Ames IA 2014.
13. Lisci**andro GR**. Chapter 9: The Thoracic (TFAST) Exam. In Focused Ultrasound for the Small Animal Practitioner, Editor, Lisciandro GR. Wiley Blackwell: Ames IA 2014.
14. **Lisciandro GR** and Armenise A. Chapter 16: Focused or COAST^3 - CPR, Global FAST and FAST ABCDE. In Focused Ultrasound for the Small Animal Practitioner, Editor, Lisciandro GR. Wiley Blackwell: Ames IA 2014.
15. Rademacher N, Pariaut R, Pate J, *et al*. Transthoracic lung ultrasound in normal dogs and dogs with cardiogenic pulmonary edema: a pilot study. *Vet Radiol Ultrasound* 2014; 55(4):447–52.
16. Hwang TS, Yoon YM, Jung DI, Yeon SC, Lee HC. Usefulness of transthoracic lung ultrasound for the diagnosis of mild pneumothorax. *J Vet Sci* 2018;19(5):660–666.

17. Vezzosi T, Mannucci T, Pistoresi A *et al*. Assessment of lung ultrasound B-lines in dogs with different stages of chronic valvular heart disease. *J Vet Intern Med* 2017;31(3):700–704.
18. Armenise A, Boysen S, Rudloff E, *et al*. Veterinary focused assessment sonography for trauma (Vet-FAST)—airway, breathing, circulation, disability and exposure (ABCDE)—in 64 canine trauma patients. *J Small Anim Pract*. 2019;60(3):173–182.
19. Lichtenstein D, Mesiere G, Biderman P, Gepner A. The lung point: an ultrasound sign specific to pneumothorax. *Intensive Care Med* 2000;26:1434–1440.
20. Lichtenstein D, Mesiere G, Biderman P, Gepner A. The lung pulse: an ultrasound sign of complete atelectasis. *Intensive Care Med* 2003;29:1930–1939.
21. Nazerian P, Volpicilli G, Vanni S, *et al*. Accuracy of lung ultrasound for the diagnosis of consolidations when compared to chest computed tomography. *Am J Emerg Med* 2015;33:620–625.
22. Kulhavy DA, **Lisciandro GR**. Use of a Lung Ultrasound Examination Called Vet BLUE to Screen for Metastatic Lung Nodules in The Emergency Room. *Abstract, J Vet Emerg Crit Care 2015; 25(S1);S14.*
23. **Lisciandro GR**. Evaluation of initial and serial combination focused assessment with sonography for trauma (CFAST) examination of the thorax (TFAST) and abdomen (AFAST) with the application of an abdominal fluid scoring system in 49 traumatized cats. Abstract, *J Vet Emerg Crit* Care 2012; 22(2): S11.

Global FAST® Integration for Patient Monitoring and Rapidly Ruling Out the Hs and Ts of Treatable Shock

Emerald Coast Veterinary Conference, Sandestin, FL, USA
Gregory R. Lisciandro, DVM, Dipl. ABVP, Dipl. ACVECC
Hill Country Veterinary Specialists & FASTVet.com, Spicewood, Texas USA
Email LearnGlobalFAST@gmail.com
Cell 210.260.5576
Website FASTVet.com

Textbook Point-of-care Ultrasound Techniques for the Small Animal Practitioner, 2nd Edition, Wiley ©2021

Global FAST® For Patient Monitoring

Global FAST® is the combined use of AFAST®, TFAST® and Vet BLUE® as a single ultrasound exam. Global FAST® is unique in screening both body cavities and is a standardized format that includes 15 acoustic windows or views.

Global FAST® can do the following with no additional views from its standardized 15 view format:

- AFAST® and its target-organ approach for obvious soft tissue abnormalities
- AFAST® and its abdominal fluid scoring system and categorizing small volume versus large volume hemorrhagic and non-hemorrhagic effusions
- AFAST® Cysto-Colic View Formula for urinary bladder volume estimation and urine output
- AFAST® Spleno-Renal View in right lateral for pneumoperitoneum
- AFAST® Hepato-Renal Umbilical View for gastrointestinal motility
- TFAST® for pleural and pericardial effusion
- TFAST® for pneumothorax (PTX)
- TFAST® for semi-quantitating and tracking PTX through the use of the Lung Point
- TFAST® echocardiography views for problems with volume, contractility, and left- and right-sided heart conditions
- TFAST® for obvious soft tissue abnormalities of the heart and thorax
- TFAST®-AFAST® for characterization of the caudal vena cava and hepatic veins for volume status
- Vet BLUE® regional, pattern-based approach for respiratory assessment
- Vet BLUE® B-line Scoring System
- Vet BLUE® Visual Lung Language for types of lung consolidation

Performing Global FAST® Most Efficiently

There are 2 major ways to efficiently perform Global FAST® and we refer to these as Global FAST blends of its 3 components.

In a standing patient, the left Vet BLUE® views are performed first, followed by a depth change for the left TFAST® PeriCardial Site view followed by the Diaphragmatico-Hepatic (DH) View and then continuing with a standing AFAST® with a Focused Spleen. The sonographer then moves to the right side of the patient and performs the right Vet BLUE® followed by the TFAST® echocardiography views at right PeriCardial Site followed by the final AFAST® HR5thBonus View. The external placement of the probe is the same for AFAST® whether the patient is standing or in right lateral recumbency. If AFAST® is negative for free fluid in standing, then lateral recumbency is not necessary. If AFAST® is positive for free fluid then when safe to do so, place the patient either right or left lateral recumbency and wait 3 minutes for fluid to re-distribute, followed by AFAST® fluid scoring. See the Global FAST® video at FASTVet.com under Free Resources.

If the patient arrives and is best left in lateral recumbency the following order is described. When in right lateral recumbency, the AFAST® and Focused Spleen are performed first, then the left Vet BLUE®, left TFAST® PeriCardial Site view followed by the right TFAST® PeriCardial Site view for TFAST® echocardiography. The patient then must be moved to access the right Vet BLUE® to complete the Global FAST® and AFAST® HR5th Bonus View. The analogous approach would be used when the patient is in left lateral recumbency.

AFAST®

The Abdominal Fluid Scoring System

Small animals are preferably in right lateral because it facilitates right TFAST® Pericardial Site views including the 4 TFAST® Echocardiography Views (short-axis left ventricular view, short-axis LA:Ao ratio, and long-axis 4-chamber view, long-axis left ventricular outflow track). Either lateral recumbency, however, is validated for AFAST® abdominal fluid scoring was originally as follows: an abdominal fluid score (AFS) of "1" is assigned to any positive AFAST view thus making the scoring system range from 0-4.

Thus, an abdominal fluid score (AFS) of "1" is a positive at any *single* AFAST® view; and an AFS of "2" positive at any two views; and an AFS of "3" positive at any 3 views; and an AFS of "4" positive at all 4 AFAST® views. The AFS gives more objective semi-quantitative assessment for effusions over terms like "trivial", "mild", "moderate" and "severe" allowing for better tracking of effusions as static (no change in score), resolving (lower score), and worsening (higher score). Very importantly, the actual AFAST® views are recorded as positive or negative, thus potentially providing support for the origin of the effusion in lower scoring patients. As an example, if a bleeding patient has an initial AFS of 1, scoring positive at the DH View, and then progresses to an AFS of 4 and requires exploratory surgery to stop the bleeding, logic would dictate that the region of the DH View is likely the origin of hemorrhage. If only "AFS 1" is recorded without location, this information is lost.

Modification of the AFAST®-Abdominal Fluid Scoring System

More recently the author modified the AFS to account for smaller pockets of free fluid as a score of "1/2" rather than a full "1." In cats and dogs, an AFS of "1/2" is assigned when the fluid pocket's maximum dimension is ≤5mm and ≤ 1cm, respectively. This modification better classifies patients that have combinations of small and larger fluid pockets. The use of this modification is based on more recent clinical studies (Lisciandro et al. 2020). *See AFAST® Proceedings for more detail.*

Making Sense of the AFS in The Bleeding Patient

In cases of hemorrhage, the AFS help categorize intra-abdominal bleeding as small volume bleeding, AFS <3, versus large volume bleeding, AFS ≥3. AFS <3 (1/2 to 2 1/2) dogs and cats do not have enough intra-abdominal hemorrhage for anemia. Thus, if a dog or cat has an AFS <3 and is anemic, there are the following 4 major scenarios in the acute setting: 1) pre-existing anemia, 2) bleeding somewhere else thus do Global FAST® and look internally - pleural cavity, retroperitoneal space, pericardial sac and lung; and consider gastrointestinal, urinary, and reproductive tracts, as well as fracture sites, 3) hemodilution (less common with graduated fluid administration strategies), or 4) lab error. Conversely, when AFS is ≥ 3 then the patient is considered as having potentially life-threatening hemorrhage having enough intra-abdominal hemorrhage to predictably become anemic.

The AFAST® Cysto-Colic Urinary Bladder Volume Formula

At the AFAST Cysto-Colic View the urinary bladder is imaged in longitudinal (sagittal) and the best largest oval is acquired in this plane and measured followed by transverse orientation and acquiring the largest oval which is measured. Measurements in (cm) will give you an estimation of urinary bladder volume in (ml) by using Length

x Width x Height (cm) x 0.625 (Lisciandro and Fosgate 2017). With measurements over time, urine output may be non-invasively estimated.

The AFAST® Spleno-Renal View for Pneumoperitoneum

Air rises and fluid falls into gravity dependent regions we refer to as "pouches." Thus, in right lateral recumbency, the Spleno-Renal View, least gravity view where air would rise, is used to screen for the enhanced peritoneal stripe sign of pneumoperitoneum. The concept is easy to understand once explained as free air is continuous with the hyperechoic peritoneal lining or body wall. If an anechoic gap exists, then the air is from the gastrointestinal tract and not free air. Ultrasound is extremely sensitive for free air and post-operative cases are an excellent way to learn the detection of pneumoperitoneum since most have free air from their laparotomy. When free air is suspected, radiography is an excellent confirmatory imaging modality.

The AFAST® Hepato-Renal Umbilical View for Gastrointestinal Motility

The stomach/proximal duodenum and the jejunum may be observed for peristalsis, expecting 4-5 minute^{-1} and 1-3 minute^{-1}, respectively, if food is present in the canine gastrointestinal tract, helping detect ileus. With food absence, including intentional fasting, ileus occurs in normalcy and must be placed into clinical context.

TFAST® Echo Views

Left Ventricular Short-axis View For Volume and Contractility

The left ventricular short-axis view (LVSA) is acquired just below the mitral valves at the level where the chordae tendinae come off the left papillary muscles referred to as the short-axis "mushroom" view. The filling and size of the "mushroom" is a reflection of patient volume status. Contractility is also assessed subjectively. Poor filling indicating poor volume can be supported or refuted by assessing the caudal vena cava; and contractility by triggering complete echocardiography. A patient thought to have poor contractility, i.e., dilated cardiomyopathy, may be treated and better stabilized during the delay of acquiring complete echocardiography. Your "Global FAST® Non-echo Fallback View" for volume status is characterization of the caudal vena cava and its associated hepatic veins at the AFAST®-TFAST® DH View.

Long-axis 4-chamber View and Its Right Ventricular (RV) to Left Ventricular (LV) Ratio (RV:LV)

The normal RV:LV ratio is 1:3-4 or the RV being a small triangle when compared to the LV being a much larger triangle. When the RV is nearly the same size of the LV, then right heart problems should be suspected, and complete echocardiography is indicated as right sided heart disease is present until proven otherwise. By recognizing the abnormality of right heart enlargement, therapy may be adjusted to better avert complications. In acute respiratory distress, the finding of an enlarged RV suggests massive PTE and Vet BLUE is used to search for the "Wedge Sign" in upper lung regions. Your "Global FAST® Non-echo Fallback View" for right-sided heart problems is characterization of the caudal vena cava and its associated hepatic veins at the AFAST®-TFAST® DH View.

Left Ventricular Short-axis for The Left Atrial (LA) to Aortic (Ao) Ratio (LA:Ao)

The normal LA:Ao Ratio is <1.3 (dogs) and <1.6 (cats) and the most challenging TFAST® echocardiography view. Your "Global FAST® Non-echo Fallback" strategy is performing the easier, less stressful, Vet BLUE®. Dry lung all Vet BLUE® views rapidly rules out any clinically relevant left-sided *congestive* heart failure (Lisciandro et al. 2016).

The Non-Echo Fallback Views for Left- and Right-sided Cardiac Problems

Remembering each is fairly straight forward - left-sided *congestive* heart failure must have lung edema (Vet BLUE®); and right-sided *congestive* heart failure must have hepatic venous congestion and thus an enlarged caudal vena caval and branching of hepatic congestion at the AFAST®-TFAST® DH View.

Characterizing the Caudal Vena Cava and Hepatic Veins

The caudal vena cava (CVC) where it traverses the diaphragm reflects volume status, an approximation for central venous pressure (CVP). Eyeball and characterize the CVC as being 1) "FAT" or distended with a maximum height > 1.0 cm in smaller dogs <9kg and >1.5cm in dogs 9kg along with a <10% change in height, high CVP, and called a fluid intolerant CVC, or 2) "flat" or collapsed with a maximum height <0.3 cm in smaller dogs < 9kg and <0.5cm in dogs > 9kg along with a <10% change in height, low CVP, and called a hypovolemic CVC, or 3) having a "bounce" (~35-50% change in diameter, in the ballpark of normal CVP) called a fluid responsive CVC. *See the CVC Chart with maximum height measurements at FASTVet.com under Free Resources.*

Measuring the CVC

Using M-mode can be challenging and difficult with a lot of patient movement and prone to error by not having the optimal sonographic plane. B-mode is another option and used by freezing and rolling the cine ball for minimal and maximal diameter measurements over several seconds that include the cardiac and respiratory cycle. Scrolling for the maximum and minimum heights can be used to calculate its distensibility index (change in CVC max and CVC min/maximum diameter of CVC x 100%). However, absolute height measurements have been created for dogs and are generally much easier (and faster) than calculations. *See the CVC Chart with maximum height measurements at FASTVet.com under Free Resources.*

Use of The Lung Point for Diagnosing and Monitoring Pneumothorax (PTX)

The use of the Lung Point is a means to increase the sensitivity for the diagnosis of PTX and to track worsening or resolving PTX and help with decision-making regarding need for thoracocentesis. For example, post lung lobe aspirate, chest tube placement/removal, during anesthesia and mechanical ventilation, or other invasive thoracic procedures, the Lung Point semi-quantifies the degree of PTX. The use of the "TFAST® PTX 1/3s Rule" helps track and semi-quantitate the degree of pneumothorax, has been developed and is used by the author.

Table Using the Author's "TFAST® PTX 1/3s Rule" for the Location of the "Lung Point" to Categorize the Degree of Pneumothorax (PTX) and for Monitoring

Location of the "Lung Point" with the Patient in Standing or Sternal and Categorizing the Degree of Pneumothorax (PTX) - General Guidelines	
Upper 1/3 of thorax	***Trivial PTX*** - Expect Mild If Any Clinical Signs
Middle 1/3 of thorax	***Moderate PTX*** - Expect Increased Respiratory Effort
Lower 1/3 of thorax	***Severe PTX*** - Expect Overt Respiratory Distress
Not Found along thorax	***Indeterminate Study*** or Most Severe form of PTX - Look at Your Patient's Respiratory Effort!
Dr. Gregory Lisciandro, Hill Country Veterinary Specialists, FASTVet.com, Spicewood, Texas, Copyright 2019.	

Use of Vet BLUE® - Dry Lung, Wet Lung, Shred Sign, Tissue Sign, Nodule Sign and Wedge Sign

By using the Vet BLUE® regional, pattern-based approach, aspiration pneumonia, left-sided congestive heart failure/volume overload, pulmonary thromboembolism, and non-cardiogenic forms of lung edema may be rapidly sorted out point-of-care. *See the Vet BLUE® Proceedings.*

Global FAST® for Rapidly Detecting Treatable Forms of Shock - The Hs AND Ts of CPR

Knowing Your American Heart Association Hs and Ts for Rapidly Detecting Treatable Conditions during CPR or Imminent Cardiopulmonary Arrest (CPA). The veterinary profession should be well commended for standardizing CPR Guidelines through RECOVER. However, the reason why your patient is going to experience CPA, or why you are doing CPR in the first place has been overlooked. Global FAST® can rapidly detect treatable causes for imminent CPA and help rapidly detect treatable causes for CPR when minutes count and decisions need to be made. Global FAST® rapidly detects treatable conditions point-of-care easily missed or only suspected based on traditional means of physical exam, laboratory testing, and radiography. The RUSH (Rapid Ultrasound in Shock) exam in human medicine was developed for these same reasons.

Global FAST® Rapidly Evaluates the Veterinary Hs & Ts of the American Heart Association (AHA) Guidelines for Treatable Causes of CPR.

The author has modified the AHA Hs and Ts. The Ts are ruled out as follows: **T**ension PTX by presence of A-lines without a lung sliding and the search for the Lung Point; **T**rauma Hemorrhage through the detection of free fluid in the intra-abdominal cavity, the retroperitoneal space, the pleural cavity and the pericardial sac, and the presence of B-lines during Vet BLUE® in trauma patients; **PTE** is diagnosed by the severe dilation of the RV during TFAST and the RV:LV Ratio, and/or the presence of the Wedge Sign in dorsal views during Vet BLUE®; and **T**amponade at the FAST DH View with or without additional PCS views; and **T**oxin-Anaphylaxis by the observation of the gallbladder halo sign, intramural edema causing sonographic striation of the gallbladder wall. However, gallbladder wall edema is not pathognomic for canine anaphylaxis. *A chart with the causes for gallbladder wall edema can be found in the Free Resources page of FASTVet.com*

Table: Use of Global FAST® for Rapidly Ruling Out your Veterinary Hs and Ts in patients nearing CPA and during CPR modified by the Gregory Lisciandro, DVM from AHA CPR Guidelines.

Knowing Your Veterinary Hs and Ts During Shock, Cardio-Pulmonary Arrest and Advanced Life Support and Using Global FAST® for Rapid Point-of-Care Detection	
The Hs Evaluated for Using Venous Blood Gas, Physical Exam, Vital Signs, and Global FAST®	**The Ts** Evaluated for Using Global FAST®
Hypothermia	**Tension PTX** (TFAST)
Hypotension (AFAST®, TFAST®, Vet BLUE®)	**Trauma, Hemorrhage** (AFAST®, TFAST®, Vet BLUE®)
Hyperkalemia, Hypokalemia	**Thromboembolism (PTE)** (TFAST® echo views, Vet BLUE®)
Hypoglycemia	**Tamponade, Pericardial Effusion** (TFAST®, AFAST®-TFAST® DH View)
Hydrogen Ion (Acidosis)	**Toxin, Anaphylaxis** (AFAST®-TFAST® DH View)
Hypertension, Pulmonary (TFAST® echo views, AFAST®-TFAST® DH View)	
Hypocontractility, DCM (TFAST® echo views, AFAST®-TFAST® DH View)	

What the Global FAST® Approach has Over the RUSH Exam

- AFAST® Abdominal Fluid Scoring System
- AFAST® Target-Organ Approach
- AFAST® CC Urinary Bladder Volume Estimation Formula and Urine Output Overtime
- AFAST® for Pneumoperitoneum
- AFAST® for Gastrointestinal Motility
- TFAST® PTX 1/3s Rule for Semi-quantifying Degree of Pneumothorax (PTX) and for Monitoring PTX
- Vet BLUE® as Regional, Pattern-based Approach for Respiratory Conditions
- Vet BLUE® B-line Scoring System

Baseline Admission Global FAST® & Serial Exams are Key

The use of repeat Global FAST® exams cannot be overemphasized. Minimally a 4-hour post-admission exam should be performed (sooner in questionable or unstable patients), and the author incorporates Global FAST® as part of daily rounds immediately after a complete physical exam.

Summary of Global FAST® for Patient Volume Status & CPR & ALS

The use of the Global FAST® is an effective, point-of-care evaluation that is non-invasive and low risk for critical patients providing invaluable information for patient volume status during resuscitation and during advanced life support (ALS) post-CPR. Furthermore, Global FAST® should be used as standard of care for rapidly surveying for treatable and reversible causes of uncharacterized hypotension/shock and CPR as well as comoplications after return to spontaneous circulation (ROSC). By incorporating Global FAST®, many conditions missed by traditional training without ultrasound are detected cageside with low patient impact, and clinical course is modified and adjusted earlier in their course. As a result lives are saved, complications better avoided, and next best tests are better determined by "seeing" the problem list with evidence-based information.

References & Further Reading

1. **Lisciandro GR**. Focused abdominal (AFAST) and thoracic (TFAST) focused assessment with sonography for trauma, triage and monitoring in small animals. *J Vet Emerg Crit Care* 2011;20(2):104-122 .
2. **Lisciandro GR**. The use of the diaphragmatico-hepatic (DH) views of the abdominal and thoracic focused assessment with sonography for triage (AFAST/TFAST) examinations for the detection of pericardial effusion in 24 dogs (2011-2012). *J Vet Emerg Crit Care 2016; 26(1):125-31.*
3. **Lisciandro GR**, Fosgate GT. Use of AFAST Cysto-Colic View Urinary Bladder Measurements to Estimate Urinary Bladder Volume in Dogs and Cats. *J Vet Emerg Crit Care, in press, January 2016.*
4. **Lisciandro GR** and Armenise A. Chapter 16: Focused or COAST^3 - CPR, Global FAST and FAST ABCDE. *In* Focused Ultrasound for the Small Animal Practitioner, Editor, Lisciandro GR. Wiley Blackwell: Ames IA 2014.
5. McMurray J, Boysen S, Chalhoub S. Focused Assessment with Sonography in Non-trauma dogs and cats in the emergency and critical care setting. Abstract. *J Vet Emerg Crit Care,* 2014; 24(S1):S28.
6. Breitkreutz R, Price S, Steiger HV, et al. 2010. Focused echocardiographic evaluation in life (FEEL) support and peri-resuscitation of emergency patients: A prospective trial. *Resuscitation* 81: 1527-33.

7. Breitkreutz R, Walcher F, Seeger FH, et al. 2007. Focused echocardiographic evaluation in resuscitation management (FEER): Concept of an advanced life support–conformed algorithm. *Crit* Care *Med* 35(S5):1527-33.
8. Lichtenstein D. 2012. Fluid administration limited by lung sonography: the place of lung ultrasound in assessment of acute circulatory failure (the FALLS-protocol). *Expert Rev Respir Med* 6(2):155-62.
9. Ferrada P, Evans D, Wolfe L et al. Findings of a randomized controlled trial using limited transthoracic echocardiogram (LTTE) as a hemodynamic monitoring tool in the trauma bay. J Trauma Acute Care Surg 2013;76(1):31-38.
10. Marik PE, Callazo R. Does Central Venous Pressure Reflect Fluid Responsiveness? An Updated Meta-analysis and a Plea for Some Common Sense. Crit Care Med 2013;41(7):1774-81.
11. Neumar RW, Otto CW, Link MS, et al. 2010. Part 8: Adult advanced cardiovascular life support: 2010 American Heart Association guidelines for cardiopulmonary resuscitation and emergency cardiovascular care. *Circulation* 122:S729-S767.
12. Perera P, Mailhot T, Riley D, Mandavia D. The RUSH exam: Rapid Ultrasound in SHock in the evaluation of the critically lll. Emerg Med Clin North Am 2010; 28(1):29-56.
13. **Lisciandro GR**. Chapter 3: Point-of-care Ultrasound. *In:* Small Animal Diagnostic Ultrasound, edited by Mattoon JS, Sellon R, and Berry CR. Elsevier: St. Louis, MO, *In Press* 2019.
14. **Lisciandro GR.** The cardiac gallbladder: Case series of 13 dogs and 1 cat with sonographically-detected gallbladder wall edema. Abstract. *J Vet Emerg Crit Care*, *In Press* 2019.
15. Dicker SA, **Lisciandro GR**, Newell SM, et al. Diagnosis of pulmonary contusions with point-of-care lung ultrasonography and thoracic radiography compared to thoracic computed tomography in dogs with motor vehicle trauma: 29 cases (2017-2018). *In Press,* 2019.
16. Hnatsusko AL, Gicking JC, **Lisciandro GR**. Anaphylaxis-related hemoperitoneum in 11 dogs. J *Vet Emerg Crit Care*, *In Press* 2019.
17. **Lisciandro GR**. Editor, Point-of-care Ultrasound Techniques for the Small Animal Practitioner, 2nd Edition, Wiley-Blackwell: St. Louis, ©2021.
18. **Lisciandro GR.** Cageside Ultrasonography in the Emergency Room and the Intensive Care Unit. *Vet Clin North Am* 2020;50(6):1445-1467.